

Medicines Adverse Reactions Committee

Meeting date	13/06/2019	Agenda item	3.2.2												
Title	Carbimazole and congenital malformations														
Submitted by	Medsafe Pharmacovigilance Team	Paper type	For advice												
Active ingredient	Product name	Sponsor													
Carbimazole	Neo-Mercazole Tablet	AFT Pharmaceuticals Ltd													
PHARMAC funding	Funded by PHARMAC and listed on the Hospital Medicines List														
Previous MARC meetings	None														
International action	EMA PRAC meeting on 26-29 November 2018 – data from epidemiological studies and case reports strengthens the evidence that carbimazole can cause congenital malformations when administered during pregnancy ¹ .														
<i>Prescriber Update</i>	None														
Classification	Prescription medicine														
Usage data	<p>Table 1: The number of people who received a dispensing of carbimazole (From DataPharm²):</p> <table border="1"> <thead> <tr> <th>Year</th> <th>Number of people who received a dispensing</th> </tr> </thead> <tbody> <tr> <td>2014</td> <td>8,769</td> </tr> <tr> <td>2015</td> <td>9,070</td> </tr> <tr> <td>2016</td> <td>9,029</td> </tr> <tr> <td>2017</td> <td>9,359</td> </tr> <tr> <td>2018</td> <td>9,704</td> </tr> </tbody> </table>			Year	Number of people who received a dispensing	2014	8,769	2015	9,070	2016	9,029	2017	9,359	2018	9,704
Year	Number of people who received a dispensing														
2014	8,769														
2015	9,070														
2016	9,029														
2017	9,359														
2018	9,704														
Advice sought	<p>The Committee is asked to advise whether:</p> <ul style="list-style-type: none"> • there is sufficient strengthened evidence that carbimazole can cause congenital malformations when administered during pregnancy • updates to the New Zealand data sheets and consumer medicine information should be requested • this topic requires further communication other than MARC's remarks in <i>Prescriber Update</i>. 														

Table of Contents

1	PURPOSE.....	3
2	BACKGROUND.....	3
2.1	Carbimazole.....	3
2.2	Usage data in New Zealand	4
2.3	Hyperthyroidism in pregnancy	4
2.4	Guidance on hyperthyroidism in pregnancy.....	5
2.4.1	New Zealand Formulary.....	5
2.4.2	BPAC article – Management of thyroid dysfunction in adults	5
2.4.3	The Endocrine Society – Clinical guidelines on the management of thyroid dysfunction	5
2.5	Carbimazole and congenital malformations	6
2.5.1	New Zealand data sheet.....	6
2.5.2	New Zealand consumer medicine information	8
2.6	Actions taken by international regulators	8
2.6.1	European Medicines Agency (EMA).....	8
2.6.2	Medicines and Healthcare products Regulatory Agency (MHRA) in the UK.....	10
2.6.3	Health Products Regulatory Authority (HPRA) in Ireland.....	10
3	SCIENTIFIC INFORMATION.....	11
3.1	Published literature.....	11
3.1.1	Song et al, 2017 ⁷	11
3.1.2	Khan et al, 2017 ¹⁶	12
3.1.3	Sachs et al, 2016 ¹⁷	13
3.1.4	Batra et al, 2015 ¹⁸	14
3.2	CARM data.....	14
3.3	Adis Insight ¹⁹	14
4	DISCUSSION AND CONCLUSIONS.....	19
5	ADVICE SOUGHT	20
6	REFERENCES	20

1 PURPOSE

In November 2018, the Pharmacovigilance Risk Assessment Committee (PRAC) of the European Medicines Agency (EMA) concluded that data from epidemiological studies and case reports strengthens the evidence that carbimazole can cause congenital malformations when administered during pregnancy¹. The PRAC recommended amendments to the product information (ie, data sheets and consumer medicine information)¹.

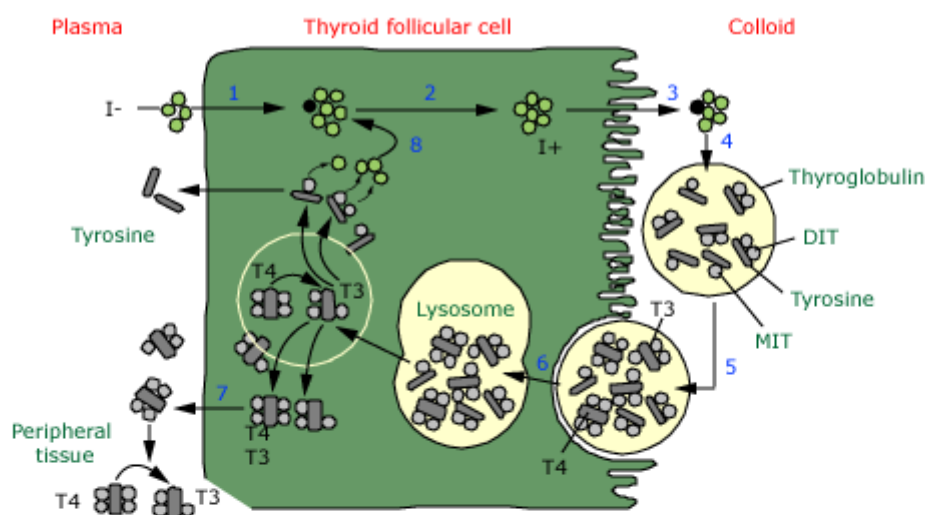
The purpose of this paper is to review the risk of fetal harm when carbimazole is administered during pregnancy.

2 BACKGROUND

2.1 Carbimazole

Carbimazole is a thionamide³. Thionamide compounds inhibit thyroid hormone synthesis⁴. They are actively transported into the thyroid gland where they inhibit both the organification of iodine to tyrosine residues in thyroglobulin and the coupling of iodotyrosines. Figure 1 below shows thyroid hormone biosynthesis⁴.

Figure 1: Thyroid hormone biosynthesis



Thyroid hormone synthesis includes the following steps: (1) iodide (I^-) trapped by the thyroid follicular cells; (2) diffusion of iodide to the apex of the cells; (3) transport of iodide into the colloid; (4) oxidation of inorganic iodide to iodine and incorporation of iodine into tyrosine residues within thyroglobulin molecules in the colloid; (5) combination of two DIT molecules to form tetraiodothyronine (T₄) or of MIT with DIT to form T₃; (6) uptake of thyroglobulin from the colloid into the follicular cell by endocytosis, fusion of the thyroglobulin with a lysosome, and proteolysis and release of T₄, T₃, DIT, and MIT; (7) release of T₄ and T₃ into the circulation; and (8) deiodination of DIT and MIT to yield tyrosine. T₃ is also formed from monodeiodination of T₄ in the thyroid and in peripheral tissues.

T₄: thyroxine; T₃: triiodothyronine; DIT: diiodotyrosine; MIT: monoiodotyrosine.

Source: Ross DS. 2018. Thionamides: Side effects and toxicities 31 August 2018. In *UpToDate*.
URL: www.uptodate.com/contents/thionamides-side-effects-and-toxicities (accessed 17 May 2018).

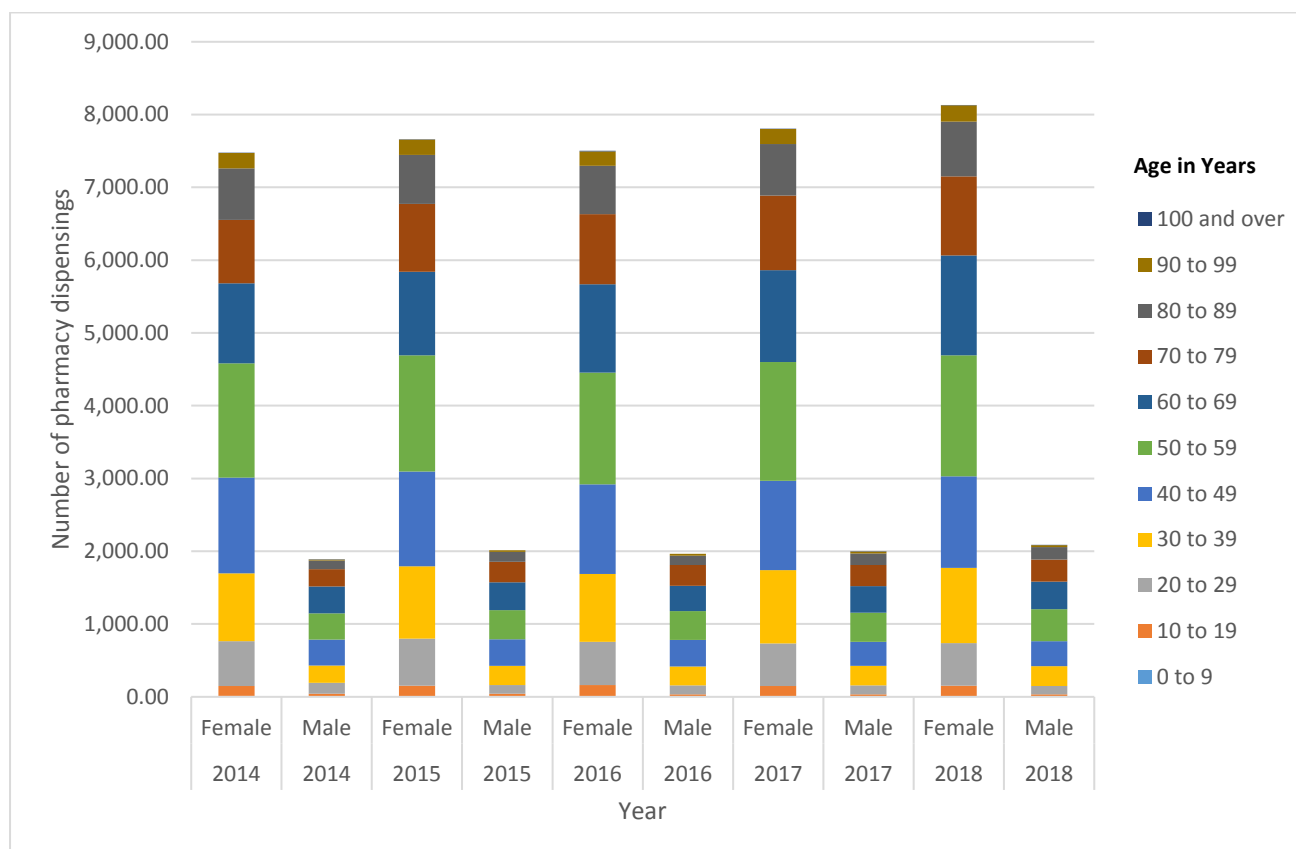
Thionamides have been associated with possible teratogenic effects⁴.

In New Zealand, the only medicine containing the active ingredient carbimazole is Neo-Mercazole 5 mg tablet⁵. Neo-Mercazole is indicated for thyrotoxicosis and hyperthyroidism⁵ (see section 2.5.1).

2.2 Usage data in New Zealand

The graph in Figure 2 shows the number of community pharmacy dispensings of carbimazole in New Zealand in 2014-2018.

Figure 2: Number of community pharmacy dispensings for carbimazole in New Zealand, 2014-2018



Source: Pharmaceutical collection data showing community pharmacy dispensings of PHARMAC-funded carbimazole

Comments:

The data in the graph is separated into females and males, with age presented in 10-year age brackets to estimate the number of women of childbearing potential who were dispensed carbimazole.

The graph shows the number of community pharmacy dispensings is much higher for females compared to males. This aligns with hyperthyroidism being more common in women than men (ratio 5:1)⁶.

2.3 Hyperthyroidism in pregnancy

The prevalence of hyperthyroidism during pregnancy is approximately 0.1–0.2%⁷. Graves' disease is the most common cause of gestational hyperthyroidism⁷.

Hyperthyroidism during pregnancy should be carefully treated because it can result in adverse maternal and neonatal outcomes⁷. Treatment options for hyperthyroidism include surgical treatment (partial or complete thyroidectomy), radioactive iodine, and antithyroid drugs⁷. Surgery and radioactive iodine therapy, however, are rarely used during pregnancy⁷. Surgery should be reserved as the last line of treatment for the minority of severe cases of gestational hyperthyroidism and should only be performed during the second trimester of

pregnancy⁷. Radioactive iodine therapy is contraindicated during pregnancy because of the increased risk of subsequent fetal thyrotoxicosis⁷.

Therefore antithyroid agents, including carbimazole, have become the standard treatment for hyperthyroidism during pregnancy⁷.

There is also the potential for women with hyperthyroidism taking carbimazole to become pregnant.

2.4 Guidance on hyperthyroidism in pregnancy

2.4.1 New Zealand Formulary

The New Zealand Formulary entry for carbimazole, includes the following information regarding pregnancy³:

Pregnancy: neonatal goitre and hypothyroidism; has been associated with congenital defects including aplasia cutis of the neonate.

Also⁸:

Radioactive iodine therapy is contra-indicated during pregnancy. Propylthiouracil and carbimazole can be given but the blocking-replacement regimen is not suitable. Rarely, carbimazole has been associated with congenital defects, including aplasia cutis of the neonate, therefore propylthiouracil remains the drug of choice during the first trimester of pregnancy. In the second trimester, consider switching to carbimazole because of the potential risk of hepatotoxicity with propylthiouracil. Both propylthiouracil and carbimazole cross the placenta and in high doses may cause fetal goitre and hypothyroidism—the lowest dose that will control the hyperthyroid state should be used (requirements in Graves' disease tend to fall during pregnancy).

2.4.2 BPAC article – Management of thyroid dysfunction in adults

In 2010, the Best Practice Advocacy Centre New Zealand (BPAC) published an article on the management of thyroid dysfunction in adults⁹. The article includes the following about hyperthyroidism in pregnancy⁹.

Pregnant women with hyperthyroidism may be at increased risk of fetal loss, pre-eclampsia, heart failure, premature labour and having a low birth-weight infant.

Thionamides are the preferred treatment choice in pregnancy. It is appropriate to use the lowest possible dose needed to control symptoms and achieve euthyroidism. In the last trimester many women can cease their anti-thyroid medication. Aiming for a FT4 in the upper third of the normal reference range for non-pregnant women may minimise the risk of fetal hypothyroidism.

Of the thionamides, propylthiouracil is preferred (but is only available via the Exceptional Circumstances scheme) as carbimazole has been associated with rare teratogenic effects. Propylthiouracil has rarely been associated with significant liver toxicity and some guidelines recommend changing from propylthiouracil back to carbimazole after the first trimester. A block and replace regimen is not suitable in pregnancy because thionamides cross the placenta in excess of levothyroxine and may result in fetal hypothyroidism and goitre.

Propylthiouracil is not listed on the Pharmaceutical Schedule, but can be made available for patients meeting specific criteria, where there is no suitable alternative.

Graves' thyrotoxicosis frequently relapses postpartum. Monitoring of thyroid stimulating hormone at six weeks postpartum and if symptoms recur is appropriate.

Radioactive iodine is contraindicated in pregnancy and for six months pre-conception.

2.4.3 The Endocrine Society – Clinical guidelines on the management of thyroid dysfunction

In 2007, The Endocrine Society (an international society of endocrinologists) published clinical guidelines on the management of thyroid dysfunction during pregnancy and postpartum¹⁰. The clinical guidelines conclude¹⁰:

Management of thyroid diseases during pregnancy requires special considerations because pregnancy induces major changes in thyroid function, and maternal thyroid disease can have adverse effects on the pregnancy and the fetus. Care requires coordination among several healthcare professionals. Avoiding maternal (and fetal) hypothyroidism is of major importance because of potential damage to fetal neural development, an increased incidence of miscarriage, and preterm delivery. Maternal hyperthyroidism and its treatment may be accompanied by coincident problems in fetal thyroid function. Autoimmune thyroid disease is associated with both increased rates of miscarriage, for which the appropriate medical response is uncertain at this time, and postpartum thyroiditis. Fine-needle aspiration cytology should be performed for dominant thyroid nodules discovered in pregnancy. Radioactive isotopes must be avoided during pregnancy and lactation. Universal screening of pregnant women for thyroid disease is not yet supported by adequate studies, but case finding targeted to specific groups of patients who are at increased risk is strongly supported.

The clinical guidelines also state¹⁰:

It should be noted that methimazole and its progenitor carbimazole are the only medications available in many countries, and therefore these drugs must be employed despite the potential complications cited. However, where available, propylthiouracil is preferred as the initial therapy for maternal hyperthyroidism.

Comments:

The guidelines for treating hyperthyroidism in pregnancy, although consistent, have not been updated for some time. The BPAC article acknowledges on the website that the item is eight years and five months old, therefore some content may no longer be current.

Propylthiouracil is not currently available in New Zealand but it is still funded by PHARMAC via special authority.

2.5 Carbimazole and congenital malformations

2.5.1 New Zealand data sheet

The New Zealand data sheet for Neo-Mercazole 5 mg tablets includes the following information relating to use in pregnancy⁵:

4.1 Therapeutic Indications

Primary thyrotoxicosis, even in pregnancy.

Secondary thyrotoxicosis – toxic nodular goitre.

However, Neo-Mercazole really has three principal applications in the therapy of hyperthyroidism:

1. Definitive therapy – induction of a permanent remission.
2. Preparation for thyroidectomy.
3. Before and after radio-active iodine treatment.

4.4 Special warnings and precautions for use

The use of Neo-Mercazole in non-pregnant women of childbearing potential should be based on individual risk/benefit assessment (see Pregnancy and Lactation).

4.6 Fertility, pregnancy and lactation

Category C

Hyperthyroidism should be treated during pregnancy. Neo-Mercazole and its active metabolite cross the placenta which may cause fetal hypothyroidism and thyroid hyperplasia but, provided the mother's dose is within the standard range, and her thyroid status is monitored, there is no evidence of neonatal thyroid abnormalities.

Studies have shown that the incidence of congenital malformations is greater in the children of mothers whose hyperthyroidism has remained untreated than in those to whom treatment with Neo-Mercazole has been given. However, very rare cases of congenital malformations have been observed following the use of Neo-Mercazole or its active metabolite methimazole during pregnancy. A causal relationship between these malformations, especially choanal atresia, oesophageal atresia and aplasia cutis congenita (congenital scalp defects), transplacental and diaplacental exposure to Neo-Mercazole and methimazole cannot be excluded.

In humans, the fetal thyroid gland begins to trap iodine 10-12 weeks after conception. Transient thyroid function abnormalities have been reported in new-borns born to mothers treated with Neo-Mercazole during pregnancy. Therefore, the use of Neo-Mercazole in non-pregnant women of childbearing potential should be based on individual risk/benefit assessment (see Special Warnings and Special Precautions for Use).

Cases of renal, skull, cardiovascular congenital defects, exomphalos, gastrointestinal malformation, umbilical malformation and duodenal atresia have also been reported. There is clear evidence of a risk for the unborn child (development of goitre or of cretinism). Graves' disease occurs in about 0.05 to 0.2% of pregnant women. Hyperthyroidism of the fetus leads to miscarriages or to premature birth in 20% of cases, and the number of stillbirths among cases of hypertrophy of the thyroid gland is considerable. There is an increased risk of premature craniosynostosis.

The possibility of replacing Neo-Mercazole with propylthiouracil should furthermore be taken into consideration, since this antithyroid drug has not resulted so far in any thyroid modifications at all in the unborn child. Some authors prefer surgical treatment.

Therefore, Neo-Mercazole should be used in pregnancy only when propylthiouracil is not suitable. If a pregnant woman takes Neo-Mercazole or a female patient becomes pregnant during treatment, they must be informed of the possible risks for the unborn child and the dose of Neo-Mercazole must be regulated by the patient's clinical condition to achieve a normal thyroid function for the mother, but without causing hypothyroidism of the fetus.

In such cases, particularly careful monitoring is required in weeks 10 to 14 of pregnancy due to the fact that the fetus will start to produce the hormone in this period. The thyroid gland of the fetus does not start to develop until week 11 of pregnancy and only becomes functional around week 18. Treatment can therefore be continued until the third month. The lowest dose possible should be used, and this can often be discontinued three to four weeks before term, in order to reduce the risk of neonatal complications and hypothyroidism precisely at a time when the brain of the fetus will be growing most. The dosologies will need to be adjusted to obtain normal thyroid function or mild maternal hyperthyroidism in order to limit the risk of fetal hypothyroidism. Maternal supplementation with L-thyroxine, T3 and T4 in order to prevent fetal hypothyroidism is a controversial issue and might prove ineffective for the fetus because it barely crosses the placenta. The blocking-replacement regimen should not be used during pregnancy since very little thyroxine crosses the placenta in the last trimester.

A prenatal exam (ultrasound) should be considered in order to detect some of the above cited malformations and to monitor the fetal thyroid gland. A neonatal thyroid function test should be performed.

Neo-Mercazole and its active metabolite are secreted in breast milk and, and due to the risk of neonatal hypothyroidism and agranulocytosis at high doses if treatment is continued during lactation, the patient should not continue to breast-feed her baby or switch to treatment with propylthiouracil, since the latter passes into breast milk about ten times less freely than does thiamazole. Breast-feeding can be carried out if the infant's thyroid function is monitored.

Comments:

Category C comes from the Australian categorisation system for prescribing medicines in pregnancy and means:

Drugs which, owing to their pharmacological effects, have caused or may be suspected of causing, harmful effects on the human fetus or neonate without causing malformations. These effects may be reversible. Accompanying texts should be consulted for further details.

For further details refer to the Therapeutic Goods Administration website in

Australia: www.tga.gov.au/australian-categorisation-system-prescribing-medicines-pregnancy

2.5.2 New Zealand consumer medicine information

The New Zealand consumer medicine information for Neo-Mercazole 5 mg tablets includes the following information relating to use in pregnancy¹¹:

Before you start to take it

Tell your doctor if you:

- are pregnant or plan to become pregnant

Neo-Mercazole is not generally recommended for use in pregnancy unless the benefits of treatment outweigh the risk to the unborn baby.

If there is a need to take Neo-Mercazole when you are pregnant your doctor will discuss the risks and benefits to you and the unborn baby.

If you have not told your doctor about any of the above, do so before you start taking Neo-Mercazole.

While you are taking Neo-Mercazole

Things you must do

IMPORTANT

Tell your doctor if you become pregnant while taking Neo-Mercazole.

Comments:

In the current New Zealand data sheet and consumer medicine information the risk of congenital malformations with carbimazole is acknowledged but considered very rare. The use of Neo-Mercazole in non-pregnant women of childbearing potential is based on individual risk/benefit assessment.

2.6 Actions taken by international regulators

2.6.1 European Medicines Agency (EMA)

2.6.1.1 11-14 June 2018 meeting¹²

The PRAC considered carbimazole/thiamazole and new information on the known risk of birth defects and neonatal disorders in case of exposure during pregnancy.

Following the publications by Song et al (2017), Khan et al (2017), Sachs et al (2016), Batra et al (2015) (all four publications are presented in section 3.1 of this report) new information on the known risk of birth defects and neonatal disorders in case of exposure during pregnancy was identified by France. Germany confirmed that the signal needed initial analysis and prioritisation by the PRAC.

2.6.1.2 26-29 November 2018 meeting¹

The PRAC considered carbimazole/thiamazole. New information on the known risk of birth defects and neonatal disorders in case of exposure during pregnancy was reviewed.

Based on the assessment of the available data sources, the PRAC considered that data from epidemiological studies and case reports strengthens the evidence that carbimazole/thiamazole can cause congenital

malformations when administered during pregnancy. Therefore, the product information was amended as described below (new text underlined):

Summary of product characteristics

4.4. Special warnings and precautions for use

Women of childbearing potential and pregnancy

Women of childbearing potential have to use effective contraceptive measures during treatment. The use of carbimazole in pregnant women must be based on the individual benefit/risk assessment. If carbimazole is used during pregnancy, the lowest effective dose without additional administration of thyroid hormones should be administered. Close maternal, fetal and neonatal monitoring is warranted (see section 4.6).

4.6. Fertility, pregnancy and lactation

Women of childbearing potential

Women of childbearing potential have to use effective contraceptive measures during treatment (see section 4.4).

Pregnancy

Hyperthyroidism in pregnant women should be adequately treated to prevent serious maternal and fetal complications.

Carbimazole is able to cross the human placenta.

Based on human experience from epidemiological studies and spontaneous reporting, carbimazole is suspected to cause congenital malformations when administered during pregnancy, particularly in the first trimester of pregnancy and at high doses.

Reported malformations include aplasia cutis congenita, craniofacial malformations (choanal atresia; facial dysmorphism), exomphalos, oesophageal atresia, omphalo-mesenteric duct anomaly, and ventricular septal defect.

Carbimazole must only be administered during pregnancy after a strict individual benefit/risk assessment and only at the lowest effective dose without additional administration of thyroid hormones. If carbimazole is used during pregnancy, close maternal, fetal and neonatal monitoring is recommended (see section 4.4).

Package leaflet (ie, consumer medicine information)

2. What you need to know before you take carbimazole

Warnings and precautions

Carbimazole can cause harm to an unborn baby. If you could get pregnant, use reliable contraception from the time you start treatment and during treatment.

Pregnancy

Carbimazole can cause harm to an unborn baby.

If you could get pregnant, use reliable contraception from the time you start treatment and during treatment.

If you are pregnant, think you may be pregnant or are planning to have a baby, tell your doctor straight away. Your treatment with carbimazole may need to be continued during pregnancy if the potential benefit outweighs the potential risk to you and your unborn baby.

Comments:

Following the recommendations of the PRAC, the use of carbimazole in pregnant women is still based on the individual risk/benefit assessment. However, the advice now focuses women of child bearing potential

and so provides a recommendation on contraception and the use of carbimazole during pregnancy, particularly in the first trimester of pregnancy and at high doses.

The recommendations from the PRAC regarding thiamazole are exactly the same as carbimazole so have not been included.

2.6.2 Medicines and Healthcare products Regulatory Agency (MHRA) in the UK

2.6.2.1 Drug Safety Update February 2019¹³

The MHRA published an article regarding carbimazole and the increased risk of congenital malformations with strengthened advice on contraception. The following advice was provided for healthcare professionals:

- carbimazole is associated with an increased risk of congenital malformations when used during pregnancy, particularly in the first trimester of pregnancy and at high doses (15 mg or more of carbimazole daily)
- women of childbearing potential should use effective contraception during treatment with carbimazole
- carbimazole should only be considered in pregnancy after a thorough individual assessment of benefits and risks of treatment, and only at the lowest effective dose without additional administration of thyroid hormones; close maternal, fetal, and neonatal monitoring is recommended.

2.6.2.2 Drug Safety Update March 2019¹⁴

The MHRA followed the above article with one regarding medicines with teratogenic potential: What is effective contraception and how often is pregnancy testing needed? The guidance in the article was based on the following considerations:

- The likelihood of pregnancy is not constant and can vary with changes in a woman's circumstances during treatment. Therefore, the likelihood of pregnancy should be assessed before each prescription of a medicine with known teratogenic potential.
- Pregnancy tests may not detect an early pregnancy that has occurred after unprotected sex in the preceding 3 weeks. Therefore, women should have a repeat pregnancy test 3 weeks after starting a new contraceptive method if there was any risk of pregnancy at the start of the contraceptive method, even if the first test was negative.
- Modern contraceptive methods have low failure rates (0.03–0.6%) when used reliably and consistently ('perfect use'), but failure rates are substantially higher for some methods because of user error or interactions with concomitant medicines ('typical use'). Risk of user error is higher for daily methods than for long-acting reversible contraceptive methods and is highest for methods used at time of sexual intercourse.
- Choice of contraceptive method is an individual one and can depend on a number of clinical factors as well as the woman's personal preference. However, different methods have different typical-use failure rates and durations of action, which can affect the frequency of pregnancy testing required.

Comments:

The Committee considered lithium, another medicine with teratogenic potential, at the 176th meeting on 6 December 2018.

2.6.3 Health Products Regulatory Authority (HPRA) in Ireland

The HPRA published a Direct Healthcare Professional Communication on their website with the following strengthened advice on pregnancy¹⁵:

- New review of available evidence from epidemiological studies and case reports strengthens the evidence that carbimazole/thiamazole is suspected to cause congenital malformations when administered during pregnancy, particularly in the first trimester of pregnancy and at high doses.
- Women of childbearing potential have to use effective contraceptive measures during treatment with carbimazole/thiamazole.

- Hyperthyroidism in pregnant women should be adequately treated to prevent serious maternal and fetal complications.
- Carbimazole/thiamazole must only be administered during pregnancy after a strict individual benefit/risk assessment and only at the lowest effective dose without additional administration of thyroid hormones.
- If carbimazole/thiamazole is used during pregnancy, close maternal, fetal and neonatal monitoring is recommended.

Comments:

Swissmedic in Switzerland have also published a Direct Healthcare Professional Communication on their website:

www.swissmedic.ch/swissmedic/fr/home/medicaments-a-usage-humain/surveillance-du-marche/health-professional-communication--hpc-/dhpc-neo-mercazole_carbimazol.html

This communication is not included in the references of this paper because it has not been translated.

3 SCIENTIFIC INFORMATION

3.1 Published literature

3.1.1 Song et al, 2017⁷

Objective

The aim of this study was to determine the effect of exposure to different antithyroid drugs during pregnancy on the incidence of neonatal congenital malformations.

Methods

A meta-analysis was performed to compare the incidence of neonatal congenital malformations after exposure to different antithyroid drugs during pregnancy. Twelve studies that met the inclusion criteria were included in this meta-analysis. PubMed, Embase, and CENTRAL databases were searched from inception until January 2017. Study designs included case-control studies, prospective cohort studies, and retrospective cohort studies.

Results

Twelve studies involving 8,028 participants with exposure to different antithyroid drugs during pregnancy were included in this study; however, only 10 studies involving 5,059 participants involved exposure to different antithyroid drugs exactly during pregnancy. The results indicated that exposure to methimazole/carbimazole only during pregnancy significantly increased the risk of neonatal congenital malformations compared to no antithyroid drug exposure (OR 1.88; 95% CI 1.33 to 2.65; P = 0.0004). No differences were observed between propylthiouracil exposure and no antithyroid drug exposure only during pregnancy (OR 0.81; 95% CI 0.58 to 1.15; P = 0.24).

Limitations in current evidence

There were several limitations to the study. First, unpublished studies were not included, which may have induced publication bias. Second, the quality assessment of the included studies suggested that not all the studies were of high quality, which may have affected the accuracy of the results. Third, the quality assessment of the evidence for the results ranged from very low to high, suggesting that the quality of the evidence needed further verification. Fourth, the exact time of exposure during pregnancy was not described in each individual trial. Therefore, evidence for a safer administration time of antithyroid drugs during pregnancy cannot be provided.

Conclusion

For pregnant women with hyperthyroidism, exposure to methimazole/carbimazole significantly increased the incidence of neonatal congenital malformations compared to exposure to propylthiouracil and no antithyroid drug exposure; however, no differences were observed between propylthiouracil exposure and no antithyroid drug exposure.

3.1.2 Khan et al, 2017¹⁶

Introduction

Thyroid dysfunction is common in pregnancy and has adverse fetal and maternal health consequences. A number of challenges in the management of gestational thyroid dysfunction remain unresolved including uncertainties in optimal thresholds for correction of hypothyroidism and strategies for pharmacological management of hyperthyroidism.

Methods

The authors searched PubMed for recent articles published on thyroid dysfunction in pregnancy, using various combinations of the keywords: 'thyroid dysfunction,' 'hyperthyroidism,' 'hypothyroidism,' 'levothyroxine,' 'pregnancy,' 'Graves' disease,' 'antithyroid drugs,' 'carbimazole,' 'methimazole,' and 'propylthiouracil.' The authors also searched key review articles and recent international practice guidelines focusing on key articles that have added to current understanding and practice.

Congenital abnormalities

A key concern with the use of antithyroid drugs in pregnancy is the risk of birth defects. An early report in the 1970s highlighted the link between methimazole and congenital malformations, and over the decades, various case studies and small series have helped delineate the phenotype of methimazole (or carbimazole) embryopathy. The classic cluster of anomalies termed methimazole embryopathy includes aplasia cutis, a developmental skin defect typically affecting the scalp, choanal atresia, tracheoesophageal fistula, dysmorphic facial features, and psychomotor retardation. These early reports did not document similar defects in relation to propylthiouracil, and so for many years, propylthiouracil remained the recommended choice of therapy in pregnancy.

However, with the realisation that propylthiouracil itself was associated with potentially fatal hepatotoxicity, propylthiouracil has become somewhat unsatisfactory as a substitute for carbimazole/methimazole in pregnancy.

Recent attention has now focused on the need to systematically estimate and characterise the risk of birth defects after antenatal exposure to antithyroid drugs. In the last decade, several population-level studies using a range of cohort and case-control designs are now revealing a more heterogeneous spectrum of anomalies in relation to both propylthiouracil and carbimazole/methimazole.

Expert commentary

Gestational thyroid hormone reference intervals vary according to population ethnicity, iodine nutrition, and assay method and each population should derive trimester specific reference intervals for use in pregnancy. Subclinical hypothyroidism and isolated hypothyroxinaemia are common in pregnancy but there is no consensus on the benefits of correcting these conditions. Although observational studies show potential benefits of levothyroxine on child neurocognitive function these benefits are have not been supported by two controlled trials. Carbimazole should be avoided in the first trimester of pregnancy due to risk of congenital anomalies but recent studies would suggest that this risk is present to a lesser magnitude with propylthiouracil. Current international guidelines recommend the use of propylthiouracil in the first trimester and switching to carbimazole for the remainder of pregnancy but the benefits and practicalities of this approach is unproven.

Key issues

- Gestational thyroid hormone reference intervals vary according to population ethnicity, iodine nutrition, and assay method and as a measure of good clinical practice each population should derive trimester specific reference intervals for use in pregnancy.
- Subclinical hypothyroidism and isolated hypothyroxinaemia are commonly encountered in pregnancy and one controlled trial and several observational studies would suggest benefits on obstetric outcomes in correcting these conditions.
- In contrast to the possible obstetric benefits two controlled trials have shown no benefit of antenatal levothyroxine on childhood neuro-intellectual performance in the children of women with gestational subclinical hypothyroidism and isolated hypothyroxinaemia.
- Although carbimazole is the preferred antithyroid drug in the non-pregnant population its use in the first trimester of pregnancy is problematic due to the associated risk of congenital anomalies.
- Recent cohort studies show that propylthiouracil also carries a risk of congenital anomalies, although of a lesser magnitude than carbimazole.
- Current international guidelines recommend that propylthiouracil is used in the first trimester while carbimazole is used in the rest of pregnancy but the safety and efficacy of this approach is unproven.

Comments:

This discussion paper addressed key challenges and areas of uncertainty in the management of thyroid dysfunction in pregnancy.

3.1.3 Sachs et al, 2016¹⁷

Background

Aplasia cutis congenita following in utero exposure to antithyroid drugs such as methimazole/carbimazole has been reported since 1972. Though currently included in methimazole/carbimazole embryopathy, it remains poorly characterised and is little discussed. Having seen two cases within a short period of time, the authors carried out a literature review and searched the French pharmacovigilance database for notification of cases.

Patients and methods

The authors performed a search of the literature in the Medline database using the following keywords: 'aplasia cutis congenita', 'birth skin defects', 'pregnancy' and 'drug'. All articles reporting cases of aplasia cutis congenita following in utero exposure to antithyroid drugs were included. All cases of aplasia cutis congenita under antithyroid drugs reported to French pharmacovigilance centres were analysed.

Results

Three hundred and sixty-eight articles were retrieved and 31 were analysed, including a further four, mentioned in selected articles, giving 59 cases of aplasia cutis congenita under methimazole/carbimazole reported in the literature and having an intrinsic accountability score of plausible or dubious. Aplasia cutis congenita was typically isolated, single, small in size, and localised on the median scalp area. Exposure occurred in the first weeks of gestation. There were six familial cases involving siblings. Ten aplasia cutis congenita and methimazole/carbimazole cases were reported to pharmacovigilance centres in France.

Discussion

Practitioners should be aware of aplasia cutis congenita following methimazole/carbimazole exposure in utero, whether it occurs in isolation or not. It is likely a teratogenic effect of methimazole/carbimazole enhanced by a genetic predisposition.

Comments:

The full article has not been provided because it is in French and has not been translated.

3.1.4 Batra et al, 2015¹⁸

The authors describe the outcomes of five pregnancies in a woman with Graves' disease who received medical management and underwent subtotal thyroidectomy.

The first pregnancy resulted in macerated stillbirth at 32 weeks. Fetal tachycardia was followed by intrauterine death at 30 weeks in the second pregnancy and macerated stillbirth at 26 weeks in the third pregnancy. Fetal tachycardia was detected at 17 weeks in the fourth pregnancy. Treatment with carbimazole along with thyroxine was followed by a live birth at 35 weeks; but the baby developed severe fatal neonatal thyrotoxicosis with crisis on day nine and died on day 12. Fetal tachycardia was noted in the fifth pregnancy as well and she was treated with carbimazole and thyroxine. She delivered a male baby at 37 weeks. He developed neonatal hypothyroidism on day eight which was controlled with thyroxine.

Comments:

A quick literature search did not result in any more recent studies of carbimazole and congenital malformations.

3.2 CARM data

Up to 31 March 2019, the Centre for Adverse Reactions Monitoring (CARM) has received two case reports of congenital malformations and carbimazole. These two reports are summarised in Table 2 below:

Table 2: Case reports of carbimazole and congenital malformation, received by CARM

Date	Reactions	Drugs		Age	Sex	
July 1973	Cleft palate	Ferrous succinate Thyroxine Carbimazole		28	Pregnant Female	
October 1999	Limb malformation	Carbimazole		9m	Male	

3.3 Adis Insight¹⁹

The following narrative summaries of case reports were found following a search of the Adis Insight database:

Aplasia cutis congenita and choanal atresia following in-utero exposure: case report (6 February 2019, Morocco)

A male neonate (age not clearly stated) developed choanal atresia and aplasia cutis congenita following in-utero exposure to carbimazole.

The male neonate's mother had been receiving treatment with carbimazole 40 mg daily initially prior to pregnancy for Graves' disease followed by 30 mg daily during initial week of pregnancy. However, due to late diagnosis of pregnancy at the 12th week, the dose of carbimazole was reduced to 20 mg (second trimester) followed by 10 mg till the full term. At the end of 39 weeks of gestation, she delivered a male baby with a height of 49 cm, cranial perimeter of 33.5 cm and weight of 3.2 kg. Neonatal examination was suggestive of choanal atresia due to lack of progression of the aspiration probe and alternating cyanosis assignor to cry. Nasofibroscope examination confirmed bilateral choanal atresia.

The male neonate underwent a left-sided choanal dilatation under unspecified local anaesthesia and a nasal tube for 72 hours. The evolution was satisfactory with resolution of respiratory distress. His mother reported that the neonate experienced respiratory difficulties and persistent mouth breathing during episodes of nasopharyngitis. At one year of age, clinical examination showed parieto-occipital anaplasia cutis congenita. Endoscopic exploration revealed persistent and bilateral choanal atresia; completely on the right-side and incompletely on the left-side. The paranasal sinus CT scan also showed bilateral choanal atresia. He

subsequently underwent an endonasal surgery with no stent. During the follow-up nine months later, the clinical course was found to be satisfactory.

Author Comment: The teratogenic role of antithyroid drug and, in particular, imidazole derivatives (carbimazole and methimazole) is strongly evoked because of several specific abnormalities reported in the literature.

Fetal goitre secondary to fetal hypothyroidism following in utero exposure: case report (21 May 2018, United Kingdom)

A fetus developed fetal goitre secondary to fetal hypothyroidism following in utero exposure to propylthiouracil and carbimazole (not all dosages stated; maternal route not stated; gestational age at reaction onset not clearly stated; sex not stated).

The fetus's mother, a 32-year-old primigravida woman, was recently diagnosed with Graves' disease. She was being treated with propylthiouracil, which was commenced pre-pregnancy. She had a large goitre, TSH receptor-stimulating antibodies level above the upper limit of quantification and predominant T3 thyrotoxicosis. In the second trimester, propylthiouracil was switched to carbimazole. A gradual improvement was observed in maternal symptoms. However, at the 20th week of gestation, a routine anomaly scan revealed fetal goitre. Throughout the follow-up, fetal growth, liquor volume and heart rate were found to be normal. Subsequent investigation revealed central vascularisation of the goitre and accelerated bone maturation suggesting possible hyperthyroidism. Therefore, carbimazole dose was increased to 60 mg daily. However, subsequent serial ultrasound revealed progressive goitre enlargement. At 29 weeks of gestation, a fetal bleed sample investigation led to diagnosis of marked fetal hypothyroidism. The fetal goitre was considered to be due to fetal hypothyroidism secondary to transplacental passage of propylthiouracil and carbimazole (duration of treatment to reaction onset not clearly stated).

Consequently, carbimazole dose was reduced to 10mg daily. Subsequent ultrasound revealed normalisation of fetal thyroid size. Subsequently, a vaginal delivery was planned (pregnancy outcome not stated).

Author Comment: Fetal goitres may complicate maternal Graves' disease as a result of the transplacental passage of antithyroid drugs, resulting in fetal hypothyroidism.

Aplasia cutis congenita following in-utero exposure: case report (24 August 2017, Unknown)

In a study, a 2.5-months-old boy was described, who was born with aplasia cutis congenita following in-utero exposure of carbimazole (Neo-Mercazone, dosage and maternal route of administration not stated).

The woman's pregnancy was characterised by gestational diabetes and Graves disease. During the first two months of pregnancy, she received treatment with carbimazole at an unknown dose. The infant presented for a circumscribed congenital alopecia at the age of two and a half months. He was born with an alopecic and crusty zone of the vertex. An examination of infant demonstrated a median atrophic-scar zone measuring 3 x 7cm, without peripheral tuft. This was indicative of aplasia cutis congenita.

Author Comment: Aplasia cutis congenita of the median scalp of a slightly crusty alopecia in a two months and a half infant after in uterus exposure to [carbimazole] during the first trimester of pregnancy. There was no malformation associated with aplasia cutis congenita in 8 cases out of 10, but in one case there was bilateral hydrocele and in the other one isolated asymmetry of the ears.

Various congenital malformations (first report for left renal agenesis): Four case reports 27 December 2016, France)

In a retrospective, observational, multi-centre and regional study, four fetuses were described who developed congenital malformation following an in-utero exposure with carbimazole for maternal Graves' disease during the first trimester (maternal routes and dosages not stated; time to reactions onsets and outcomes not stated).

Case 1: The fetus developed interventricular septal defect following an in-utero exposure with carbimazole. The carbimazole therapy was discontinued in the third trimester.

Case 2: The fetus developed localised alopecia following an in-utero exposure with carbimazole.

Case 3: The fetus developed left renal agenesis following an in-utero exposure with carbimazole. The carbimazole therapy was continued in the second and third trimester.

Case 4: The fetus developed choanal atresia following an in-utero exposure with carbimazole. The carbimazole therapy was switched to propylthiouracil in the second trimester.

Author Comment: The malformations we observed were suggestive of the teratogenicity of carbimazole.

Embryopathy: 2 case reports (21 May 2014, Australia)

The following report describes embryopathy in two siblings, a girl and a boy, following in utero exposure to carbimazole.

The 12-year-old girl was born to a woman who had started receiving carbimazole at 30 mg daily (route not stated) at the time of conception for Graves' disease. When the mother was euthyroid, her dose was reduced to 15 mg by the third trimester. Her regular prenatal sonograms were normal and her pregnancy was uncomplicated. A female baby was born with right sided choanal atresia, hypoplastic alae nasi, arched eyebrows, upslanting palpebral fissures, bulbous nose, broad nasal bridge, telecanthus and a small left ear. She also presented with a subaortic ventriculo-septal defect which resolved by the age of four years. At the age of 12 years, she had normal growth and development. She had generalised dental spacing and was missing one premolar and one molar.

The mother received carbimazole at 15 mg daily (route not stated) for hyperthyroidism during her third pregnancy. Antenatal scans were normal. A male baby was born with mild hypospadias for which he underwent a meatoplasty. His facial features were remarkably similar to his sister. He had hypoplastic alae nasi, arched eyebrows, bulbous nose, broad nasal bridge, upslanting palpebral fissures, telecanthus and small ears. He also had generalised dental spacing, microdontia and was missing two premolars. At the age of eight years, he had normal growth and development.

Author Comment: We also considered a dosage effect of carbimazole on the fetus. Patient 1 was exposed to a larger dose (30 mg) than Patient 2 (15 mg) during the first two trimesters.

Oesophageal atresia, omphalocele and ileal prolapse following in utero exposure: case report (31 July 2013, France)

A female neonate developed oesophageal atresia, omphalocele and ileal prolapse following in utero exposure to carbimazole.

The baby's mother, who had a history of Graves-Basedow disease and a family history of mucoviscidosis, received carbimazole (Neo-Mercazole) 20 mg twice daily during the first four weeks of her pregnancy. At 22 weeks' gestation, a prenatal ultrasound revealed an omphalocele. At 35 weeks, a repeat ultrasound demonstrated a small abdominal defect for the omphalocele with few intestinal loops inside and no liver. The baby was born prematurely at 36 weeks' gestation, weighing 2690 g. Examination revealed an omphalocele measuring 50 mm in diameter, with ileal prolapse through the patent omphalomesenteric duct. She also had oesophageal atresia with tracheo-oesophageal fistula.

A primary oesophageal anastomosis was performed, followed by resection of the omphalomesenteric duct with primary intestinal anastomosis and a tension-free abdominal wall reconstruction. The girl was discharged on postoperative day 34, weighing 3130g.

Author Comment: It remains unclear whether the association is secondary to the maternal disease, the medication, or the combination of both factors. The potential teratogenicity of carbimazole, most likely acted on a predisposed genetic background.

Embryopathy following in utero exposure: Four case reports (22 May 2013, Hong Kong)

A study identified four male neonates who were born with congenital anomalies compatible with carbimazole embryopathy after their mothers received carbimazole during pregnancy for hyperthyroidism. The mothers

had taken carbimazole 5-40 mg/day from before conception until 8-15 weeks' gestation (route not stated). The children were all born with aplasia cutis; one also had a patent vitellointestinal duct, and another also had an omphalocele, which had been detected on antenatal ultrasound (outcomes not stated).

Author Comment: The authors report 'infants born to mothers treated with carbimazole during pregnancy and who had anomalies compatible with carbimazole embryopathy'.

Congenital hypoplasia of nasal cartilage in a newborn following in utero exposure: case report (3 October 2012, Turkey)

A newborn child (sex not stated) developed carbimazole embryopathy with isolated congenital hypoplasia of the lower nasal cartilage following in utero exposure to carbimazole.

The child's mother had been receiving carbimazole 20 mg/day at the time of conception (parental route not stated). From 9 to 25 weeks' gestation, her carbimazole dosage was gradually reduced to 5 mg/day. At 26 weeks' gestation, carbimazole was discontinued. She gave birth to a baby at 36 weeks' gestation. The child presented at age 2.5 years with difficulty inspiring, with apnoeic and cyanotic episodes. Examination revealed depressed alar wings and a short columella. CT scan revealed a left-sided nasal bone hypoplasia. The child underwent nasal ala reconstruction with conchal cartilaginous graft through an open rhinoplasty. During dissection, remnants of lower lateral cartilages were detected. Postoperatively, there was an acceptable projection of nasal tip with improved inspiration.

Author Comment: Here, we report another example for this type phenotype of (carbimazole) embryopathy and our surgical approach to solve the nasal problems.

Multiple congenital anomalies following in utero exposure: case report (23 March 2012, United Kingdom)

A female neonate had multiple congenital anomalies following in utero exposure to carbimazole.

The mother had Graves' disease and was receiving carbimazole 40 mg (frequency, route and duration of treatment not stated) and levothyroxine sodium at conception. After her pregnancy was discovered, carbimazole was gradually reduced reaching 10 mg/day at term, and levothyroxine sodium was stopped. The mother remained euthyroid throughout pregnancy. The baby was born at 38 weeks' gestation by forceps delivery due to fetal distress and had a birth weight of 2.78 kg. Her Apgar scores were 10 and 10 at 1 and 5 minutes, respectively. On day five of life, routine blood tests showed an elevated TSH level (13.8 mIU/L). Her thyroid hormone levels returned to normal without treatment. Further investigation revealed that she had a patent vitellointestinal duct, for which she underwent surgery at the age of five months. She also had aplasia cutis, laryngomalacia and mild facial abnormalities, including a large forehead, broad flat nasal bridge and thin upper lip. It was later discovered that she also had congenital absence of both lower lacrimal punctae and right nasolacrimal atresia.

Author Comment: The constellation of several rare but distinctive congenital anomalies in this and other published cases supports the concept of a carbimazole embryopathy and the current guidelines that carbimazole should be avoided in the first trimester of pregnancy.

Neonatal choanal atresia, tracheoesophageal fistula and clinodactyly following in utero exposure: case report (18 October 2011, France)

A male neonate was born with choanal atresia, tracheoesophageal fistula and clinodactyly following in utero exposure to carbimazole.

The neonate's mother started receiving carbimazole 25 mg twice daily (route not stated) for Graves' disease before becoming pregnant, and it was continued for the first seven weeks of gestation. The neonate was born at term. At birth, he had severe respiratory distress and required intubation and ventilation in the neonatal ICU. Endonasal endoscopic examination confirmed bilateral choanal atresia. Laryngotracheoscopy showed a congenital tracheoesophageal fistula in his upper trachea, associated with his right tracheal bronchus. The

fistula and choanal atresia were confirmed by CT scan. An examination also showed bilateral fifth-finger clinodactyly.

The neonate was referred to a genetics clinic. The malformations were attributed to carbimazole exposure during pregnancy. The choanal atresia was surgically repaired using endoscopic endonasal techniques, and the tracheoesophageal fistula was resected via a cervical approach. At one month of age, he was discharged from hospital.

Embryopathy following in utero exposure: 6 case reports (23 February 2011, France)

Retrospective review of cases reported to the French Pharmacovigilance Centre in Nice identified six instances of embryopathy following in utero exposure to carbimazole, which the neonates' mothers had received for Graves' disease.

In the first case, the 25-year-old mother started receiving carbimazole 15 mg/day at 7 weeks of amenorrhoea (WA), with a dosage increase to 25 mg/day over the course of 1 week at 8WA. One week later, she ingested carbimazole 45 mg/day for 2 days in an attempt to abort her pregnancy; however, she then decided to carry the child to term, and continued taking carbimazole 15 mg/day. At 12WA, her carbimazole dosage was decreased to 10 mg/day until 14WA, and to 5 mg/day until delivery. At 15WA, prenatal ultrasound revealed severe gastroschisis with evisceration of spleen, stomach and intestine. The mother also had a family history of cleft lip/palate. The female neonate was delivered by caesarean section at 37WA+5 days. The baby girl was intubated and ventilated, and then underwent surgical closure of the abdominal wall with good outcome.

The second patient's mother had been receiving carbimazole 45 mg/day since before pregnancy. Her dosage was decreased to 25 mg/day at 9WA, to 10 mg/day at 22WA and to 5 mg/day at 26WA. Antenatal ultrasound revealed severe omphalocele with right ureterocoele. The baby boy was delivered vaginally at 37WA, and exhibited dysmorphic facial features with nasal cartilage hypoplasia and small bilateral eyelid slits. Multiple-step surgery was successfully completed.

In the third case, the 39-year-old mother was receiving carbimazole 60 mg/day since before pregnancy. At 16WA, her carbimazole dosage was decreased to 10 mg/day, and then to 5 mg/day (according to a table, she received carbimazole 60 mg/day until 9WA, and 20 mg/day from 9–19WA). The parents were consanguineous, and maternal history included a posterior fossa tumour. The baby boy was delivered vaginally at 36WA+3 days. Examination revealed a patent vitello-intestinal duct, an ileo-umbilical fistula and a high arched palate. The neonate underwent successful surgery 12 hours after birth. However, an intestinal anastomosis disjunction occurred on day 9, and necessitated a temporary ileostomy until day 21. He had a good outcome.

The fourth patient's mother had been receiving carbimazole 20 mg/day since before pregnancy; carbimazole was stopped at 10WA. The baby girl was delivered by caesarean section at 34WA, and exhibited localised alopecia, 3 cm aplasia cutis congenita, ear helix anomaly and facial dysmorphism (treatment and outcome not stated).

The fifth case involved a male neonate born with an isolated aplasia cutis congenita at 38WA. The 36-year-old mother had a cleft lip/palate, and had fallen pregnant during treatment with carbimazole 50 mg/day. Her carbimazole dosage was decreased to 20 mg/day at 3WA, to 5 mg/day at 8WA and to 2.5mg at 23WA. The neonate's defect was not treated.

In the last case, the neonate's mother had been receiving carbimazole 60 mg/day since before pregnancy; the mother also had a history of poorly controlled insulin-dependent diabetes. Pregnancy was diagnosed at 13WA, and her carbimazole dosage was decreased to 20 mg/day until 22WA and to 10 mg/day until 26WA; therapy was then stopped. The baby girl was delivered at 37WA+3 days, and required ventilation for respiratory distress. A CT scan identified bilateral choanal atresia with membrane and bone involvement. She underwent two-phase surgical choanae perforation with favourable outcome. Other findings included a mild aortic coarctation, which was left untreated.

Author Comment: Our retrospective series of six cases should draw the attention of prescribing doctors to the risks of congenital malformations associated with the treatment of hyperthyroidism during pregnancy. The

causal effect of [carbimazole/thiamazole] in the occurrence of [aplasia cutis congenita] is well established, although certain unknowns persist regarding the association with other malformations, illustrating the complex interactions between genetic background and fetal environment, both endo- and exogenously.

Congenital abnormalities following in utero exposure: case report (21 January 2011, France)

Multiple congenital abnormalities occurred in a fetus whose mother was taking carbimazole during pregnancy.

The 40-year-old multigravida woman, who had a 6-year history of Graves' disease, had taken carbimazole (dosage and route not stated) for the 2 months prior to and during the first 4 weeks of her fourth pregnancy. An ultrasound at 23 weeks' gestation revealed tetralogy of Fallot, duodenal atresia and polyhydramnios. A female baby was delivered at 34 weeks' gestation and experienced respiratory distress immediately after birth.

The baby showed a broad forehead, short upslanting palpebral fissures, epicanthic folds, a broad nasal bridge, a small mouth, hypoplastic nipples and bilateral 5th fingers clinodactyly. An ECG revealed a ventricular septal defect, a minor pulmonary stenosis and an overriding aorta. On day 2 of life, bilateral choanal atresia was treated using thalium laser and the duodenal atresia was surgically repaired. An annular pancreas was diagnosed during surgery. At 1 month of age, the baby showed poor feeding as a result of fibrous residual stenosis of the choanae; this was treated by laser. Hypercyanotic episodes were treated with propranolol at 3 months of age. A neurological examination at 8 months of age was normal, and no mutation in the CHD7 gene was found.

Neonatal cutaneous aplasia, Roviralta syndrome and tracheomalacia following in utero exposure: case report (20 July 2010, France)

A female neonate was born with cutaneous aplasia, Roviralta syndrome and tracheomalacia following in utero exposure to carbimazole.

The mother commenced carbimazole 60 mg/day (route not stated) for hyperthyroidism associated with Graves' disease shortly before conception. During her eighth week of amenorrhoea, the mother developed hypothyroidism, and her carbimazole dosage was reduced to 30 mg/day. Pregnancy was confirmed in her twelfth week of amenorrhoea, and carbimazole was continued with regular dose modifications throughout the remainder of her pregnancy; the female neonate was born at 39 weeks' amenorrhoea. On examination, cutaneous scalp aplasia was noted, as well as an ogival palate and microretrognathism. Laboratory findings on day 3 of life showed an elevated TSH level. At 5 weeks of age, she became ill with cyanosis and regurgitation. She was diagnosed with hypertrophic pyloric stenosis with severe gastro-oesophageal reflux, hiatus hernia and incompetent cardia, consistent with Roviralta syndrome.

Pylorotomy was subsequently performed. During the procedure, the girl developed acute laryngeal dyspnoea, which revealed a minor tracheomalacia. Her clinical course was favourable, except for a transient episode of peripheral pancytopenia. She showed moderate stridor at 18 months of age, but growth and psychomotor development were normal.

Comments:

The narrative summaries of case reports all include the date they were released and the reporter country in brackets. Only case reports from the last ten years are presented.

4 DISCUSSION AND CONCLUSIONS

Antithyroid agents, including carbimazole, have become the standard treatment for hyperthyroidism during pregnancy⁶. Hyperthyroidism during pregnancy should be carefully treated because it can result in adverse maternal and neonatal outcomes¹⁴.

In November 2018, the PRAC concluded that data from epidemiological studies and case reports strengthens the evidence that carbimazole can cause congenital malformations when administered during pregnancy¹. The PRAC recommended amendments to the product information (ie, data sheets and consumer medicine

information) which are summarised in section 2.6.1 of this report. The New Zealand data sheets and consumer medicine information do not currently include these amendments.

Other regulatory agencies in Europe have published safety advice on their websites, either through publications or Direct Healthcare Professional Communications. The advice has focussed on contraception and the use of carbimazole during pregnancy, particularly in the first trimester of pregnancy and at high doses.

This report presents the literature considered by the PRAC at their November meeting. Although there has only been two cases to date in New Zealand, there have been case reports of congenital malformations with carbimazole internationally. All of this information strengthens the evidence that carbimazole can cause congenital malformations when administered during pregnancy.

5 ADVICE SOUGHT

The Committee is asked to advise whether:

- there is sufficient strengthened evidence that carbimazole can cause congenital malformations when administered during pregnancy
- updates to the New Zealand data sheets and consumer medicine information should be requested
- this topic requires further communication other than MARC's remarks in *Prescriber Update*.

6 REFERENCES

1. European Medicines Agency. 2019. *Pharmacovigilance Risk Assessment Committee (PRAC) recommendations on signals 26-29 November 2018 – Carbimazole; thiamazole – New information on the known risk of birth defects and neonatal disorders in case of exposure during pregnancy*. URL: www.ema.europa.eu/en/documents/prac-recommendation/prac-recommendations-signals-adopted-26-29-november-2018-prac-meeting_en.pdf (accessed 10 May 2019).
2. Ministry of Health. 2019. DataPharm version 13 May 2019 (data extracted from Pharmaceutical Collection on 26 March 2019). URL: <https://minhealthnz.shinyapps.io/datapharm/> (accessed 27 May 2018).
3. New Zealand Formulary. 2019. *New Zealand Formulary v83: Carbimazole* 1 May 2019. URL: https://nzf.org.nz/nzf_3792 (accessed 13 May 2019).
4. Ross DS. 2018. Thionamides: Side effects and toxicities 31 August 2018. In *UpToDate*. URL: www.uptodate.com/contents/thionamides-side-effects-and-toxicities (accessed 17 May 2018).
5. AFT Pharmaceuticals Ltd. 2018. *Neo-Mercazole New Zealand Data Sheet* November 2018. URL: www.medsafe.govt.nz/profs/Datasheet/n/Neo-Mercazoletab.pdf (accessed 13 May 2019).
6. Ross DS. 2019. Disorders that cause hyperthyroidism 12 September 2017. In *UpToDate*. URL: www.uptodate.com/contents/disorders-that-cause-hyperthyroidism (accessed 27 May 2019).
7. Song R, Lin H, Chen Y, et al. 2017. Effects of methimazole and propylthiouracil exposure during pregnancy on the risk of neonatal congenital malformations: A meta-analysis. *PLOS One* 3 July 2017. URL: www.ncbi.nlm.nih.gov/pmc/articles/PMC5495385/ (accessed 23 May 2019).
8. New Zealand Formulary. 2019. *New Zealand Formulary v83: Antithyroid drugs* 1 May 2019. URL: https://nzf.org.nz/nzf_3787#nzf_3790 (accessed 20 May 2019).
9. Best Practice Advocacy Centre New Zealand. 2010. *Management of thyroid dysfunction in adults* 2010. URL: <https://bpac.org.nz/BPJ/2010/December/thyroid.aspx> (accessed 20 May 2019).
10. The Endocrine Society. 2007. *The Endocrine Society's Clinical Guidelines: Management of Thyroid Dysfunction during Pregnancy and Postpartum*. URL: www.health.govt.nz/system/files/documents/pages/clinical-guideline-management-of-thyroid-dysfunction-during-pregnancy-postpartum.pdf (accessed 20 May 2019).
11. AFT Pharmaceuticals Ltd. 2016. *Neo-Mercazole consumer medicine information* 19 September 2016. URL: www.medsafe.govt.nz/Consumers/CMI/n/Neo-Mercazoletab.pdf (accessed 21 May 2019).
12. European Medicines Agency. 2018. *Pharmacovigilance Risk Assessment Committee (PRAC) Minutes of the meeting on 11-14 June 2018 – New signals detected from other sources – Carbimazole; thiamazole*.

URL: www.ema.europa.eu/en/documents/minutes/minutes-prac-meeting-11-14-june-2018_en.pdf (accessed 21 May 2019).

13. Medicines and Healthcare products Regulatory Agency. 2019. Carbimazole: increased risk of congenital malformations; strengthened advice on contraception. *Drug Safety Update* 12(7):1. URL: www.gov.uk/drug-safety-update/carbimazole-increased-risk-of-congenital-malformations-strengthened-advice-on-contraception (accessed 21 May 2019).
14. Medicines and Healthcare products Regulatory Agency. 2019. Medicines with teratogenic potential: what is effective contraception and how often is pregnancy testing needed? *Drug Safety Update* 12(8): 3. URL: www.gov.uk/drug-safety-update/medicines-with-teratogenic-potential-what-is-effective-contraception-and-how-often-is-pregnancy-testing-needed (accessed 21 May 2018).
15. Amdipharm Limited. 2019. *Medicinal products containing carbimazole or thiamazole (synonym: methimazole): (1) strengthened advice on contraception and (2) risk of acute pancreatitis*. URL: [www.hpra.ie/docs/default-source/default-document-library/important-safety-information---medicinal-products-containing-carbimazole-or-thiamazole-\(synonym-methimazole\).pdf?sfvrsn=0](http://www.hpra.ie/docs/default-source/default-document-library/important-safety-information---medicinal-products-containing-carbimazole-or-thiamazole-(synonym-methimazole).pdf?sfvrsn=0) (accessed 23 May 2019).
16. Khan I, Okosieme OE, Lazarus JH. 2017. Current challenges in the pharmacological management of thyroid dysfunction in pregnancy. *Expert Review of Clinical Pharmacology* 10(1): 97-109. DOI: 10.1080/17512433.2017.1253471 (accessed 27 May 2019).
17. Sachs C, Tebacher-Alt M, Mark M, et al. 2016. Aplasia cutis congenital and antithyroid drugs during pregnancy: case series and literature review. *Ann Dermatol Venereol* 143(6-7): 423-435. URL: www.ncbi.nlm.nih.gov/pubmed/27033749 (accessed 23 May 2019).
18. Batra CM, Gupta V, Gupta N, et al. 2015. Fetal hyperthyroidism: intrauterine treatment with carbimazole in two siblings. *The Indian Journal of Pediatrics* 82(10): 962-964. DOI: 10.1007/s12098-015-1744-0 (accessed 27 May 2019).
19. Adis Insight. 2019. URL: <https://adisinsight.springer.com/> (accessed 24 May 2019).