

Medicines Adverse Reactions Committee

Meeting date	14 March 2019	Agenda item	3.2.1
Title	Fingolimod and tumefactive lesions		
Submitted by	Medsafe Pharmacovigilance Team	Paper type	For advice
Active constituent Fingolimod 0.5 mg capsule	Medicine (TT50) Gilenya (TT50-8636)	Sponsor Novartis New Zealand Ltd	
Funding	Funded under special authority (SA1562) – approved by the Multiple Sclerosis Treatment Committee		
Previous MARC meetings	Fingolimod has not been discussed previously		
International action	<ul style="list-style-type: none"> – EMA: requested safety reviews via period safety update reviews (PSUR) and legislative processes; prescribing information was updated in December 2018. – [REDACTED] 		
Prescriber Update	Reminder: Immunomodulatory medicines and risk of progressive multifocal leukoencephalopathy <i>Prescriber Update</i> 37(1): 10.		
Schedule	Prescription medicine		
Usage data	2016: 1515 prescriptions dispensed to 411 people 2017: 1718 prescriptions dispensed to 447 people Source: Ministry of Health - DataPharm		
Advice sought	<p>The Committee is asked to advise whether:</p> <p>There is sufficient evidence for an association between fingolimod and tumefactive lesions, and if so:</p> <ul style="list-style-type: none"> – is a data sheet update required – does this topic require further communication, other than MARC’s remarks in <i>Prescriber Update</i>? 		

Table of Contents

1.0 PURPOSE..... 3

2.0 BACKGROUND 3

 2.1 Multiple sclerosis..... 3

 2.2 Fingolimod (Gilenya) 5

 2.2.1 Mechanism of action..... 5

 2.2.2 Disease rebound after fingolimod withdrawal..... 7

 2.2.3 Funding..... 8

 2.2.4 Usage data..... 9

 2.3 Tumefactive lesions..... 10

 2.3.1 Epidemiology 10

 2.3.2 Clinical presentation and imaging 10

 2.3.3 Pathogenesis 11

 2.3.4 Management 12

 2.4 Data sheets..... 12

 2.4.1 Gilenya New Zealand Data Sheet [10]..... 12

 2.4.2 Gilenya UK Summary of Product Characteristics [24] 16

 2.5 International regulatory action 17

 2.5.1 European Medicines Agency (EMA) 17

 [REDACTED]

3.0 SCIENTIFIC INFORMATION 17

 3.1 Published literature..... 17

 3.1.1 Tls reported during treatment with fingolimod 17

 3.1.2 Tls reported after cessation of fingolimod 19

 3.1.3 Tls reported during treatment or after cessation 23

 [REDACTED]

 [REDACTED]

 [REDACTED]

 [REDACTED]

 3.3 Individual case reports 30

 3.3.1 New Zealand..... 30

 [REDACTED]

 [REDACTED]

4.0 DISCUSSION AND CONCLUSIONS 36

5.0 ADVICE SOUGHT..... 37

 [REDACTED]

7.0 REFERENCES 37

1.0 PURPOSE

Tumefactive lesions were first identified as a possible safety signal by the European Medicines Agency (EMA) Pharmacovigilance Risk Assessment Committee (PRAC) following review of the Gilenya PSUR 8 (Periodic Safety Update Report; 1 March 2014 to 28 February 2015).

The PRAC requested the marketing authorisation holder (MAH), Novartis, to discuss the occurrence of tumefactive multiple sclerosis lesions on Gilenya treatment in subsequent PSURs and then via a legally binding procedure. This ultimately resulted in an update to the summary of product characteristics (SmPC) in December 2018 – although the update had not been published on the EMA’s website at the time that this paper was written.

Section 4.4 (Warnings and Precautions) of the EU SmPC will be updated as follows:

“Tumefactive lesions

Rare cases of tumefactive lesions associated with MS relapse were reported in the post-marketing setting. In case of severe relapses, MRI should be performed to exclude tumefactive lesions.

Discontinuation of Gilenya should be considered by the physician on a case-by-case basis taking into account individual benefits and risks.”

This paper seeks advice on whether there is sufficient evidence for an association between fingolimod and tumefactive lesions, and if so, if any regulatory activity is required.

2.0 BACKGROUND

2.1 Multiple sclerosis

Multiple sclerosis (MS) is a progressive, potentially disabling autoimmune disease of the central nervous system that damages myelin, the protective layer surrounding nerves [1]. Lymphocytes migrate out of lymph nodes into the circulation, cross the blood–brain barrier, and aggressively target putative myelin antigens in the central nervous system, causing inflammation, demyelination, neuroaxonal injury, astrogliosis, and ultimately neurodegeneration [2] (see also section 2.2.1). This disrupts communication to and from the brain, producing symptoms such as vision impairment, loss of coordination and balance, extreme fatigue, pain, bladder dysfunction, cognitive impairment, numbness, weakness, and mood changes [1].

For the majority of patients, MS leads to progressive disability over a 20–30 year time frame, with significant impacts on the patient’s quality of life, societal costs and personal expenses [2, 3]. The cause of MS is unknown but is likely due to a combination of genetic and environmental factors [3].

MS affects 2.5 million people worldwide, and approximately 85% have a relapsing form of the disease at onset (relapsing-remitting MS, RRMS) [2]. RRMS is characterised by clearly defined attacks (also known as relapses or exacerbations) with full or incomplete recovery [4]. There is minimal disease progression during the periods between disease relapses, though relapses themselves may leave severe residual disability.

The age at MS onset is typically between 20 and 35 years [5], and women are two to three times more likely to have MS than men [1].

New Zealand is a high risk country for MS with an overall age and sex standardised prevalence of 73.1 per 100,000 population [6] and an annual age standardised incidence of 3.0 per 100,000 population [7]. There is also a latitudinal gradient, with a 3-fold increase in MS prevalence and a 3.8-fold increase in incidence from the north (37°S) to the south (48°S) of New Zealand [6, 7].

Disease-modifying drugs aim to reduce the frequency of relapses as well as reducing the severity of relapses to reduce the build-up of disability. Approved and currently funded disease-modifying drugs for RRMS in New Zealand are as follows [8].

First-line treatments:

- Fingolimod (Gilenya)
- Dimethyl fumarate (Tecfidera)
- Natalizumab (Tysabri)
- Teriflunomide (Aubagio)

Second line treatments:

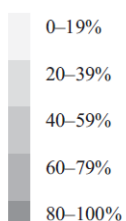
- Glatiramer acetate (Copaxone)
- Interferon beta-1-alpha (Avonex, Avonex Pen)
- Interferon beta-1-beta (Betaferon).

Clinical trials of drug treatments for MS must be conducted over long periods of time and use a variety of efficacy measures because of the fluctuating nature of RRMS and the general improvement seen after acute relapses [3]. The most durable efficacy measures are annualised relapse rate (ARR), probability of or time to sustained disability progression (increase in Expanded Disability Status Scale [EDSS] sustained for 3 or 6 months) and MRI measures of gadolinium (Gad)-enhancing or T2-weighted lesions. More recently, measures of whole brain atrophy (believed to be a surrogate marker of long term disability) have emerged. Table 1 below is a comparison (published in 2014) of the relative risk reduction (RRR) for ARR, sustained disability progression and MRI measures for MS therapies, including those available in NZ, based on data from Phase III clinical trials and Cochrane reviews [9]. Note that for the RRR measures, a higher percentage indicates a larger risk reduction.

Table 1: Comparison of 2-year efficacy for treatment of RRMS from pivotal trials/Cochrane reviews

Drug ^{ref}	β -interferon 1a IM ^{70,71}				β -interferon 1b S/C ^{75,76}			Fingolimod ⁷⁹		Natalizumab ^{81,82}		Alemtuzumab ^{8,15,16}
	Laquinimod ²³	Azathioprine ⁷²	Glatiramer acetate ^{73,74}		Teriflunomide ³	β -interferon 1a S/C ^{77,78}		Dimethyl fumarate ^{9,80}				
Year of study	1993 2010	1993	1992	1990 2008 1995	2009 2010	2004 2012						
ARR (placebo)	0.82 0.30	0.43	0.84	1.27 0.54 1.28	0.40 0.36	0.73 0.67						
Relapses (ARR RRR)	18% 23%	23%	29%	34% 32% 32%	55% 53%	68% 67%						
Disability (3m SDP RRR)	37% 36%	42%	12%	25% 30% 29%	30% 38%	54% 52%						
New Gad Lesions (RRR)	52% 37%		33%	43% 80% 88%	82% 90%	92% 94%						
New T2 Lesions (RRR)	33% 30%		31%	63% 77% 78%	75% 85%	83% 83%						
Brain Atrophy (BPF RRR)	18% 30%		11% [†]	21% [‡] 25% 32%	36% 21% [#]	2% 57%						

Key



* Figures for CARE-MS-I and CARE-MS-II adjusted to comparison with placebo
 † 9 month data from European/Canadian Glatiramer Acetate Study
 ‡ data from secondary progressive multiple sclerosis study, # combined figure for DEFINE and CONFIRM (placebo comparisons trials).
 Figures in bold statistically significant (adjusted p < 0.05).

ARR = annualised relapse rate, BPF = brain parenchymal fraction, Gad = Gadolinium enhancing, m = months, RRMS = relapsing remitting multiple sclerosis, RRR = relative risk reduction, SDP = sustained disability progression.

Source: Broadley S, Barnett M, Boggild M, et al. 2014. Therapeutic approaches to disease modifying therapy for multiple sclerosis in adults: an Australian and New Zealand perspective – Part 2 New and emerging therapies and their efficacy. *Journal of Clinical Neuroscience* 21(11): 1847-56. DOI: 10.1016/j.jocn.2014.01.018 (accessed 12 February 2019).

2.2 Fingolimod (Gilenya)

Gilenya was approved in NZ on 13 November 2011. It is indicated as a disease modifying therapy for the treatment of patients with relapsing multiple sclerosis to reduce the frequency of relapses and to delay the progression of disability [10]. Each Gilenya capsule contains 0.5 mg fingolimod, mannitol and magnesium stearate. See section 2.4 for prescribing information.

Fingolimod is a derivative of myriocin, an isolate of the fungus *Isaria sinclairii* and has immunosuppressive qualities through modulation of the sphingosine 1 phosphate (S1P) system [3].

2.2.1 Mechanism of action

2.2.1.1 Sphingosine 1-phosphate system

Sphingosine 1-phosphate is a soluble signalling molecule that is involved in immunological, cardiovascular, and neurological processes through interaction with the sphingosine 1-phosphate receptor (S1PR) [11].

The S1PR is a G protein-coupled receptor with 5 subtypes: S1PR1, S1PR2, S1PR3, S1PR4, and S1PR5. The S1PR1–3 receptors are ubiquitously expressed, whereas S1PR4 is exclusively found in lymphatic and hematopoietic tissues, and S1PR5 is predominantly found in the central nervous system [12] (Figure 1).

Because S1PR is expressed in multiple organs and systems, the S1PR axis has been implicated in several immune-mediated disorders, such as MS, rheumatoid arthritis, and inflammatory bowel diseases [11]. It is also a target for immunomodulating drug therapies, such as fingolimod.

Figure 1: Sphingosine 1-phosphate receptor subtypes, the medications that functionally antagonise them, and the tissues that each subtype is expressed in with their corresponding functions

Receptor	Drug	Associated cell types	Function
S1PR1	Fingolimod Siponimod Ozanimod Ceralifimod GSK2018682 Ponesimod MT-1303	Lymphocytes Neurons Endothelial cells AV node and Conduction system Smooth muscle	Egress from lymph nodes Neuron migration and function Permeability barrier Heart rate slowing Permeability barrier
S1PR2	X	CNS Endothelial cells Smooth muscle	Hearing and balance Permeability barrier Vascular tone
S1PR3	Fingolimod	Neurons AV node and Conduction system Endothelial cells Smooth muscle	Neuron migration and function Slowed heart conduction Permeability barrier
S1PR4	Fingolimod	Lymphocytes	Lymphoid tissue expression Dendritic and TH17 cell modulation
S1PR5	Fingolimod Siponimod Ozanimod Ceralifimod GSK2018682	CNS Natural killer cells	Oligodendrocyte function Natural killer cell migration

CCF © 2017

Key: AV = atrioventricular, CNS = central nervous system, TH17 = T helper 17.

Source: Chaudry B, Cohen J and Conway D. 2017. Sphingosine 1-phosphate receptor modulators for the treatment of multiple sclerosis. *Neurotherapeutics* 14(4): 859-73. DOI: 10.1007/s13311-017-0565-4 (accessed 12 February 2019).

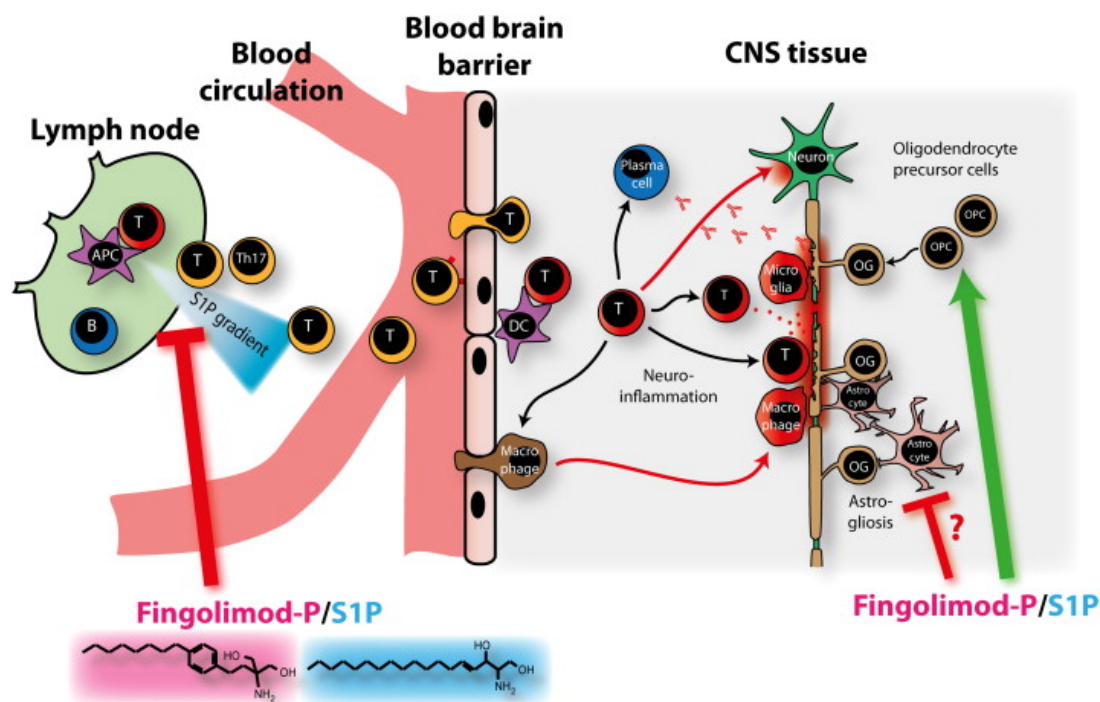
2.2.1.2 Lymphocyte redistribution

Fingolimod is a lipophilic agent that is phosphorylated by sphingosine kinase 1/2 to become fingolimod phosphate, an S1P analogue [11]. Fingolimod phosphate binds to the S1PR, leading to receptor internalisation. After fingolimod phosphate dissociation, the receptor returns to the surface. Fingolimod is nonselective and functions as a modulator of S1PR1, S1PR3, S1PR4, and S1PR5. Fingolimod inhibits lymphocyte migration through S1PR1, but its off target effects include transient bradycardia, a first dose effect mediated via S1PR1 and S1PR3 (Figure 1) [12].

Inhibiting lymphocyte migration is fingolimod’s principal mechanism of action for the treatment of multiple sclerosis. Fingolimod modulates the function of S1PR1, eventually leading to internalisation of the receptor and down-regulation at the gene expression level [12]. This process deprives lymphocytes of the S1P signal that they need to egress from the lymph nodes into inflamed tissue [12] and causes a redistribution, rather than depletion, of lymphocytes (eg, T cells) [2]. This redistribution reduces the infiltration of pathogenic lymphocyte cells into the central nervous system where they would be involved in nerve inflammation and nervous tissue damage [10] – see Figure 2.

The reduction in circulating lymphocytes is dose dependent, with a 20% to 30% decrease in the first week of treatment [11]. Fingolimod's effect is reversible, but is prolonged because of its 7-day elimination half-life.

Figure 2: A model of MS disease induction and neural repair: potential mechanisms of action of fingolimod



Notes

Fingolimod is an oral prodrug and shows structural similarities to sphingosine. In their phosphorylated forms, fingolimod-P and S1P can both bind to S1P receptors. To elicit neuroinflammation, myelin-directed T helper cells are thought to undergo a process that begins with their activation by antigen-presenting cells (APC) in peripheral lymphoid organs, such as lymph nodes (left of picture). The activated T cells then leave the lymphoid tissue, following an S1P gradient. This lymphocyte egress is inhibited by the interaction of fingolimod with S1P receptors. It has been suggested that this retention effect especially applies to peripheral interleukin-17-producing T cells. Myelin-directed T cells cross the blood–brain barrier, a process that seems to be controlled by local dendritic cells (DC). The influx of activated T cells triggers a cascade of inflammatory responses (the activation of B cells and plasma cells to produce antibodies, the recruitment of other immune cells, such as macrophages, the activation of microglia and the direct attack by T cells of the myelin sheath and the neuronal cell soma, which eventually leads to demyelination and neuronal cell death). This tissue damage evokes reactive processes, such as the recruitment and differentiation of oligodendrocyte progenitor cells (OPC), which are thought to be promoted by fingolimod. Astrogliosis or glial scarring may be inhibited by fingolimod. Thus, fingolimod may exert its clinical efficacy via immune-directed and direct CNS-mediated effects.

Source: Ingwersen J, Aktas O, Kuery P, et al. 2012. Fingolimod in multiple sclerosis: mechanisms of action and clinical efficacy. *Clinical immunology* 142(1): 15-24. URL:

<https://www.sciencedirect.com/science/article/pii/S152166161100163X> (accessed 12 February 2019).

2.2.2 Disease rebound after fingolimod withdrawal

In some patients, disease activity can surpass pre-treatment activity shortly after discontinuation of fingolimod treatment, indicating a rebound effect [13]. Patients with highly active disease before the start of treatment with fingolimod or who showed a good therapeutic response to fingolimod might be predisposed to severe rebound after withdrawal. TLs have also been reported in patients who have discontinued fingolimod and who are experiencing disease rebound [14, 15].

The pathophysiological mechanisms that have been proposed to underlie disease rebound after fingolimod cessation include the rapid influx and increase in the number of self-reactive T cells, especially central memory T cells, from lymph nodes to peripheral blood, the activation of antibody

production by T cells, and the reduction of direct S1P receptor-mediated actions on oligodendrocytes, astrocytes, and neurons [15]. However, these have not been confirmed.

Comments

Sphingosine 1-phosphate receptors are expressed throughout the body. Fingolimod's primary target is the S1P1 receptors in lymphocytes, but it has off-target effects due to its antagonism of S1P1 receptors in other tissues as well as other S1P receptors.

Rebound and severe disease exacerbation following discontinuation of fingolimod has been reported. Various mechanisms for this have been proposed but none have been confirmed. The Gilenya data sheet has recently been updated to include warnings about return of disease activity (rebound) after Gilenya discontinuation (see section 2.4.1).

2.2.3 Funding

Fingolimod was added to the community and hospital sections of the Pharmaceutical Schedule on 1 November 2014. Fingolimod is funded under Special Authority [SA1562](#), approved by the Multiple Sclerosis Treatment Assessment Committee (MSTAC). Applications are considered by MSTAC at its regular meetings and approved subject to eligibility according to the Entry and Stopping criteria (Figure 3).

The Kurtzke Expanded Disability Status Scale (EDSS) is a method of quantifying disability in MS and is used to measure and assess disability and disease progression in MS. Funded treatments, including fingolimod, are available for people with MS who have an EDSS score of 0–4.0 [16].

Figure 3: Fingolimod starting and stopping criteria

FINGOLIMOD – Special Authority see [SA1562 below](#) – Retail pharmacy

Wastage claimable

Cap 0.5 mg.....	2,200.00	28	✓ Gilenya
-----------------	----------	----	-----------

SA1562 Special Authority for Subsidy

Special Authority approved by the Multiple Sclerosis Treatment Committee

Notes: Special Authority approved by the Multiple Sclerosis Treatment Assessment Committee (MSTAC). Applications will be considered by MSTAC at its regular meetings and approved subject to eligibility according to the Entry and Stopping criteria (below).

Application details may be obtained from PHARMAC's website <http://www.pharmac.govt.nz> or:

The coordinator	Phone: 04 460 4990
Multiple Sclerosis Treatment Assessment Committee	Facsimile: 04 916 7571
PHARMAC PO Box 10 254	Email: mstaccoordinator@pharmac.govt.nz
Wellington	

Completed application forms must be sent to the coordinator for MSTAC and will be considered by MSTAC at the next practicable opportunity.

Notification of MSTAC's decision will be sent to the patient, the applying clinician and the patient's GP (if specified).

Entry Criteria

- 1) Diagnosis of multiple sclerosis (MS) must be confirmed by a neurologist. Diagnosis must include MRI confirmation; and
- 2) patients must have Clinically Definite Relapsing Remitting MS with or without underlying progression; and
- 3) patients must have:
 - a) EDSS score 0 - 4.0 and:
 - Experienced at least 1 significant relapse of MS in the previous 12 months or 2 significant relapses in the past 24 months; and
 - Evidence of new inflammatory activity on an MR scan within the past 24 months, any of the following:
 - i) a gadolinium enhancing lesion; or
 - ii) a Diffusion Weighted Imaging positive lesion; or
 - iii) a T2 lesion with associated local swelling; or
 - iv) a prominent T2 lesion that clearly is responsible for the clinical features of a recent relapse; or
 - v) new T2 lesions compared with a previous MR scan; and

- 4) A significant relapse must:
 - a) be confirmed by the applying neurologist or general physician (the patient may not necessarily have been seen by them during the relapse but the neurologist/physician must be satisfied that the clinical features were characteristic and met the specified criteria);
 - b) be associated with characteristic new symptom(s)/sign(s) or substantial worsening of previously experienced symptom(s)/sign(s);
 - c) last at least one week;
 - d) start at least one month after the onset of a previous relapse;
 - e) be severe enough to change either the EDSS or at least one of the Kurtzke Functional System scores by at least 1 point;
 - f) be distinguishable from the effects of general fatigue; and
 - g) not be associated with a fever ($T > 37.5^{\circ}\text{C}$); and
- 5) applications must be made by the patient's neurologist or general physician; and
- 6) patients must have no previous history of lack of response to fingolimod; and
- 7) patients must have not previously had intolerance to fingolimod; and
- 8) patient must not be co-prescribed beta interferon or glatiramer acetate.

Stopping Criteria

Any of the following:

- 1) Confirmed progression of disability that is sustained for six months. Progression of disability is defined as progress by any of the following EDSS points:
 - a) from starting at EDSS 0 increasing to (i.e. stopping on reaching) EDSS 3.0; or
 - b) 1.0 to 3.0; or
 - c) 1.5 to 3.5; or
 - d) 2.0 to 4.0; or
 - e) 2.5 to 4.5; or
 - f) 3.0 to 4.5; or
 - g) 3.5 to 4.5; or
 - h) 4.0 to 4.5.
- 2) increasing relapse rate over 12 months of treatment (compared with the relapse rate on starting treatment)(see note); or
- 3) intolerance to fingolimod; or
- 4) non-compliance with treatment, including refusal to undergo annual assessment.

Note: Switching between natalizumab, fingolimod, dimethyl fumarate and teriflunomide is permitted provided the EDSS stopping criteria are not met. Switching to interferon or glatiramer acetate is only permitted provided the EDSS stopping criteria are not met and both fingolimod and natalizumab are either not tolerated or treatment with both agents would be clinically inappropriate. Continued relapses on treatment would be expected to lead to a switch of treatment provided the stopping criteria are not met. If a relapse has resulted in an increased EDSS score that potentially may lead to discontinuation of treatment according to stopping criteria, a period of 6 months is allowed from the start of the relapse for recovery to occur.

Source: Pharmaceutical Management Agency. 2019. *Pharmaceutical Schedule 26(0)* January 2019: 138-9. URL: <https://www.pharmac.govt.nz/tools-resources/pharmaceutical-schedule/> (accessed 9 January 2019).

2.2.4 Usage data

The use since funding began is shown in Table 2.

Table 2: Fingolimod usage data, 2014–2017

Year	NumPharms ^a	NumPpl ^b
2014	23	20
2015	1177	364
2016	1515	411
2017	1718	447

- a. NumPharms: the number of times the pharmaceutical product is dispensed from a pharmacy to the named person as initial dispensings or all at once during the year.
- b. NumPpl: the number of people who received a dispensing of the pharmaceutical product from a pharmacy at least once during the year, as an initial dispensing or all at once (excludes people who only received a repeat dispensing during the year).

Source: Ministry of Health. 2018. DataPharm (beta) version 04 October 2018 (data extracted from Pharmaceutical Collection on 30 May 2018). URL: <https://minhealthnz.shinyapps.io/datapharm-beta/> (accessed 7 February 2019).

Comments

Use of fingolimod has steadily increased since it was first funded in November 2014. Similarly, the gross pharmaceutical spend on MS treatments continues to increase.

2.3 Tumefactive lesions

Tumefactive lesions (TLs) are large (>2 cm), tumour-like demyelinating lesions in the central nervous system (CNS) that may occur with surrounding oedema, mass effect, and ring enhancement [14]. TLs poses a diagnostic challenge as they are difficult to distinguish from true CNS neoplasms or other CNS lesions on MRI. A biopsy may be needed to make a definitive diagnosis [17]. TLs are sometimes reported in the literature as tumefactive demyelinating lesions, demyelinating pseudotumours, tumour-like demyelinating lesions and tumefactive MS lesions [14].

2.3.1 Epidemiology

TL prevalence is estimated to be 1–3 per 1000 cases of MS, with an annual incidence of 0.3 per 100,000 [14]. However, this may be an underestimate due to the unavailability of a global MS registry and under-reporting of this condition. A recent retrospective cohort study from a demyelinating disease unit in Spain, reported a relatively higher TL prevalence of 14 per 1000 MS cases [18].

TLs may be the first neurological event leading to a diagnosis of MS or they may occur in patients with pre-existing MS [14]. In a study that examined 168 pathologically confirmed TL cases, 70% of patients presented initially with TL progressed to develop MS a few years later [19]. Only 8 out of 168 (5%) had an established MS diagnosis prior to the development of TL.

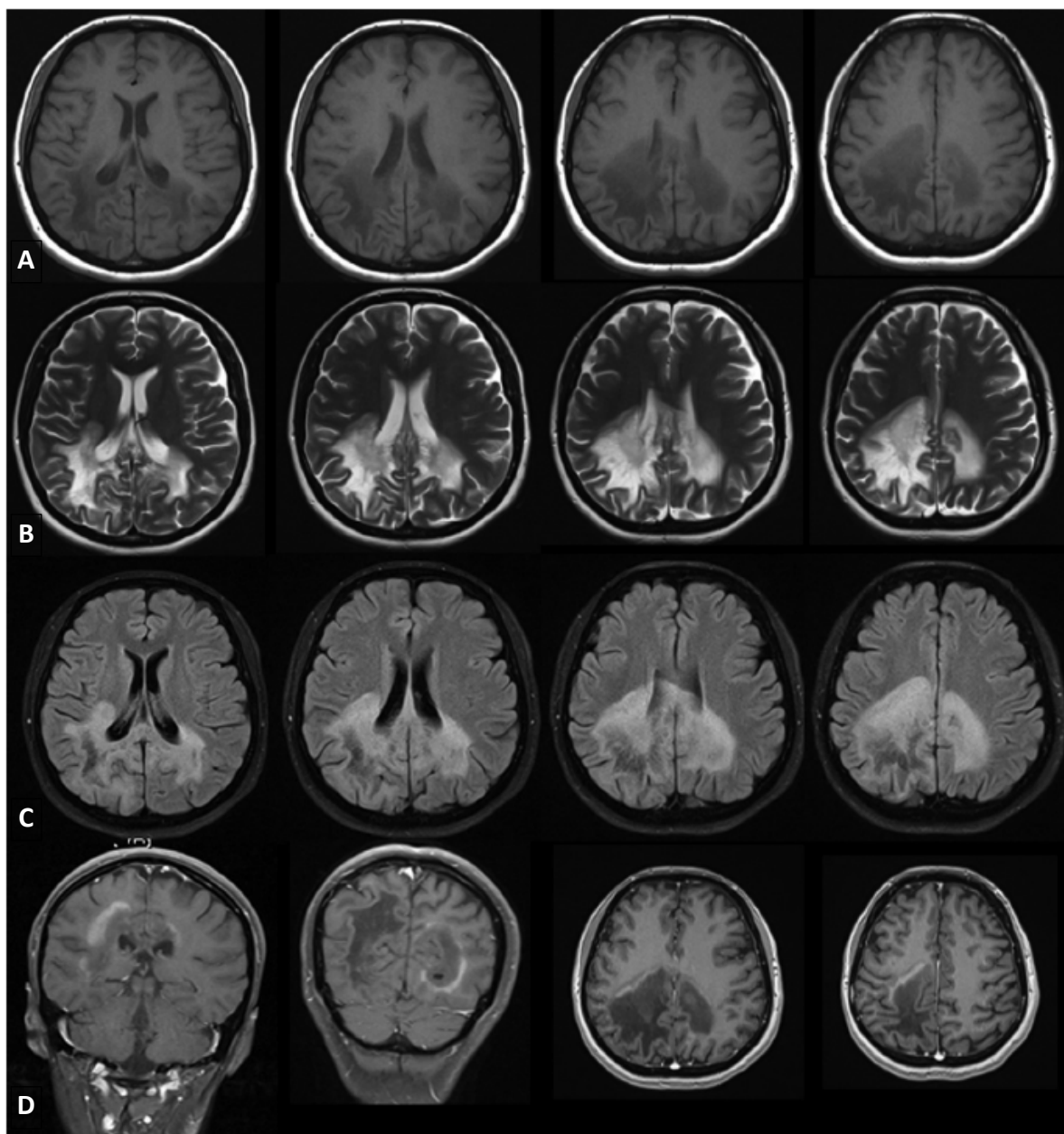
TLs may occur at any age, with those aged 20–39 years being more frequently affected [14]. This may be explained by the fact that MS is a disease that is more common in the second and third decade of life. The male to female TL ratio varies between studies, but one review of the literature found a female predominance of up to 75% with a female to male ratio of 3:1 [14]. This is in close agreement with the female to male ratio found in people with MS.

2.3.2 Clinical presentation and imaging

The clinical presentation of TL is variable due to the differences in size and location of the lesion [14]. Patients usually have multiple symptoms, which is suggestive of multifocal or diffuse CNS involvement. Motor, sensory, cognitive, and cerebellar symptoms are predominant, and they may develop at any time from days to weeks. Because TLs are often supratentorial, symptoms can include aphasia, apraxia, seizures, impaired consciousness, visual field deficits, Gerstmann syndrome, and cognitive dysfunction including hemiparesis and hemisensory disturbance.

There is no evidence that the prognosis of patients with MS and tumefactive lesions is worse than that of patients with normal lesions [18]. However, some radiological features have been analysed and it has been described that larger lesions have a worse outcome upon follow-up (median EDSS 4 in those exceeding 5 cm as opposed to median EDSS 2.5 in 1–5 cm lesions); the correlation was weak and suggested little of the EDSS can be explained by lesion size [19].

MRI is the gold standard neuroimaging modality for TL diagnosis, including 3 plane scout, sagittal fast fluid-attenuated inversion recovery (FLAIR), axial fast spin echo proton density / T2, axial fast FLAIR, and axial gadolinium enhanced T1 [14] (Figure 4).

Figure 4: MRI of the brain showing features of tumefactive lesions

A. T1-weighted images; B. T2-weighted images; C. FLAIR images; D. Gadolinium-enhanced images.

Source: Algahtani H, Shirah B and Alassiri A. 2017. Tumefactive demyelinating lesions: a comprehensive review. *Multiple Sclerosis and Related Disorders* 14: 72-9. DOI: 10.1016/j.msard.2017.04.003 (accessed 12 February 2019).

2.3.3 Pathogenesis

The pathogenesis of TL remains unknown [14]. Antibody-mediated and B cell-mediated immunological mechanisms may play a role as well as inflammatory cytokines such as tumour necrosis factor- α and interleukin-1 β , which are toxic to both myelin and oligodendrocytes.

Fingolimod has been reported as a causative agent for TL, both upon initiation of therapy and after its cessation. Hypotheses on the underlying mechanism of fingolimod-induced TLs are diverse and include: unusual activation of immune system, redistribution of immune cells, lymphocyte subset shift (eg, increase in CD8+ in peripheral blood and CNS, which can be cytotoxic), transient inhibition of regulatory cells, and the role of altered S1P1 receptor genotype [13, 14, 20-23].

2.3.4 Management

Management of TLs is based on whether the patient is known to have MS or a history of prior demyelinating lesion or the patient is unknown to have MS or is presenting with a new disease onset [14]. Treatment of acute lesions includes corticosteroids and plasma exchange therapy. In MS patients, conventional first line MS disease modifying therapy should be used.

In their review of TLs, Algahtani et al [14] stated that recently published data suggests that fingolimod should not be used in TL patients, mainly due to the possibility of more than just a chance association between TLs and initiation of fingolimod. Natalizumab should also be avoided; there may also be a theoretical risk of TL in RRMS patients using alemtuzumab.

Comments

Tumefactive lesions are difficult to diagnose and there are varying estimates for prevalence and incidence. TLs have been identified in patients before and after MS is diagnosed, and during and after disease modifying treatment, including in association with fingolimod.

When TLs have been reported in association with fingolimod, there is no particular pattern for the TTO, whether the TLs occurred during therapy or after discontinuation, and patients' MS clinical and treatment history before the TLs were diagnosed.

2.4 Data sheets

2.4.1 Gilenya New Zealand Data Sheet [10]

2.4.1.1 Indications

GILENYA is indicated as a disease modifying therapy for the treatment of patients with relapsing multiple sclerosis to reduce the frequency of relapses and to delay the progression of disability [10].

2.4.1.2 Dose and method of administration

One 0.5 mg capsule, once daily.

After the first dose, all patients should be observed, with hourly pulse and blood pressure measurement, for a period of 6 hours for signs and symptoms of bradycardia. All patients should have an electrocardiogram performed prior to dosing and at the end of the 6-hour monitoring period.

Not indicated for use in children. No dose adjustments required based on gender or ethnicity, or in patients with renal impairment, mild or moderate hepatic impairment. Use with caution in patients aged ≥ 65 years and older, with severe hepatic impairment or diabetes mellitus.

2.4.1.3 Contraindications

Gilenya is contraindicated in patients:

- who in the last 6 months had myocardial infarction, unstable angina pectoris, stroke/transient ischemic attack, decompensated heart failure (requiring inpatient treatment), or New York Heart Association Class III/IV heart failure
- with severe cardiac arrhythmias requiring anti-arrhythmic treatment with Class Ia or Class III anti-arrhythmic drugs
- with second-degree Mobitz type II atrioventricular (AV) block or third-degree AV block, or sick-sinus syndrome, if they do not have a pacemaker
- patients with a baseline QTc interval ≥ 500 msec)
- with known hypersensitivity to fingolimod or any of the excipients.

2.4.1.4 Special warnings and precautions for use

Prior treatment with immunosuppressive and immunomodulating therapies

When switching from other disease modifying therapies to Gilenya, the half-life and mode of action of the other therapy must be considered in order to avoid additive immune suppressive effects, whilst at the same time, minimizing the risk of disease reactivation. Before initiating treatment with Gilenya, a recent CBC (i.e. after discontinuation of prior therapy) should be available to ensure any immune effects of such therapies (e.g. cytopenia) have resolved.

- Beta interferon, glatiramer acetate, dimethyl fumarate – start Gilenya immediately
- Natalizumab – caution; elimination of natalizumab can take up to 2-3 months following discontinuation
- Teriflunomide – caution; elimination can take several months to up to 2 years (see teriflunomide data sheet for an accelerated elimination procedure)
- Alemtuzumab – not recommended

Return of disease activity (rebound) after Gilenya discontinuation

Cases of severe exacerbation of disease have been reported after stopping Gilenya in the post-marketing setting. This was generally observed within 12 weeks after stopping Gilenya, but was also reported up to and beyond 24 weeks after Gilenya discontinuation. Therefore, caution is indicated when stopping Gilenya therapy. If discontinuation of Gilenya is deemed necessary, patients should be monitored for relevant signs and symptoms and appropriate treatment should be initiated as required.

Stopping Gilenya therapy

If a decision is made to stop treatment, the physician needs to be aware that fingolimod remains in the blood and has pharmacodynamic effects, such as decreased lymphocyte counts, for up to two months following the last dose. Lymphocyte counts typically return to the normal range within 1-2 months of stopping therapy. Starting other therapies during this interval will result in a concomitant exposure to fingolimod. Use of immunosuppressants soon after the discontinuation of Gilenya may lead to an additive effect on the immune system and therefore caution should be applied.

2.4.1.5 Undesirable effects

Clinical trials

The safety population of Gilenya is derived from two Phase III placebo-controlled clinical trials (FREEDOMS and FREEDOMS II) and one Phase III active-controlled (interferon beta-1a) clinical trial (TRANSFORMS) in patients with relapsing remitting multiple sclerosis. It includes a total of 2431 patients on GILENYA (0.5 or 1.25 mg dose). Table 3 shows the frequency of ADRs in pooled analysis of the placebo-controlled trials.

Table 3: Tabulated summary of fingolimod adverse drug reactions - pooled analysis of two placebo-controlled trials

Adverse drug reactions	Placebo N=773 (%)	Fingolimod 0.5 mg N=783 (%)	Frequency for 0.5 mg dose
Infections			
Influenza	65 (8.4)	89 (11.4)	very common
Sinusitis	64 (8.3)	85 (10.9)	very common
Bronchitis	35 (4.5)	64 (8.2)	common
Herpes zoster	7 (0.9)	16 (2.0)	common
Tinea versicolour	3 (0.4)	14 (1.8)	common
Pneumonia*	1 (0.1)	7 (0.9)	uncommon
Neoplasms benign, malignant and unspecified (incl cysts and polyps)			
Basal cell carcinoma	5 (0.6)	14 (1.8)	common
Melanoma	2 (0.3)	1 (0.1)	uncommon**
Kaposi's sarcoma	0	0	Very rare**
Cardiac Disorders			
Bradycardia	7 (0.9)	20 (2.6)	common
Nervous system disorders			
Headache	175 (22.6)	192 (24.5)	very common
Dizziness	65 (8.4)	69 (8.8)	common
Migraine	28 (3.6)	45 (5.7)	common
Seizure	7 (0.9)	2 (0.3)	uncommon

continued overleaf

	Placebo N=773 (%)	Fingolimod 0.5 mg N=783 (%)	Frequency for 0.5 mg dose
Adverse drug reactions			
Posterior reversible encephalopathy syndrome (PRES)	0 (0.0)	0 (0.0)	rare*
Gastrointestinal disorders			
Diarrhoea	74 (9.6)	99 (12.6)	very common
General disorders and administration site conditions			
Asthenia	6 (0.8)	15 (1.9)	common
Musculoskeletal and connective tissue disorders			
Back pain	69 (8.9)	78 (10.0)	very common
Skin and subcutaneous tissue disorders			
Eczema	15 (1.9)	21 (2.7)	common
Pruritus	17 (2.2)	21 (2.7)	common
Investigations			
Hepatic enzyme increased (ALT, GGT, AST increased)	32 (4.1)	119 (15.2)	very common
Blood triglycerides increased	7 (0.9)	16 (2.0)	common
Respiratory, thoracic and mediastinal disorders			
Cough	87 (11.3)	96 (12.3)	very common
Dyspnoea	54 (7.0)	71 (9.1)	common
Eye disorders			
Vision blurred	19 (2.5)	33 (4.2)	common
Macular oedema	3 (0.4)	4 (0.5)	uncommon
Vascular disorders			
Hypertension	28 (3.6)	63 (8.0)	common
Blood and lymphatic system disorders			
Lymphopenia	2 (0.3)	53 (6.8)	common
Leucopenia	1 (0.1)	17 (2.2)	common

* Not reported in Study FREEDOMS, FREEDOMS II and TRANSFORMS. The frequency category was based on an estimated exposure of approximately 10,000 patients to fingolimod in all clinical trials

**The frequency category and risk assessment were based on an estimated exposure of more than 24,000 patients to fingolimod 0.5 mg in all clinical trials.

Post-marketing

Table 4 shows post-marketing ADRs.

Table 4: Adverse drug reactions from spontaneous reports and literature (frequency not known)

Immune system disorders
Hypersensitivity reactions, including rash, urticaria and angioedema upon treatment initiation
Gastrointestinal disorders
Nausea
Musculoskeletal and connective tissue disorders
Myalgia, arthralgia
Nervous system disorders
Severe exacerbation of disease after discontinuation (see section 4.4 Special warnings and precautions for use).

2.4.1.6 Pharmacodynamic effects

With continued daily dosing, the lymphocyte count decreases over a two week period to approximately 30% of baseline. Low lymphocyte counts are maintained with chronic daily dosing. The majority of T and B lymphocytes regularly traffic through lymphoid organs and these are the cells mainly affected by fingolimod. Approximately 15-20% of T lymphocytes have an effector memory phenotype, cells that are important for peripheral immune surveillance. Since this lymphocyte subset typically does not traffic to lymphoid organs it is not affected by fingolimod. Peripheral lymphocyte count increases are evident within days of stopping fingolimod treatment and typically normal counts are reached within one to two months. Chronic fingolimod dosing leads to a mild decrease in the neutrophil count to approximately 80% of baseline. Monocytes are unaffected by fingolimod.

Comments

Tumefactive lesions are not listed in the NZ Gilenya data sheet.

Severe exacerbation of disease after discontinuation was added to the warnings and precautions and post-marketing sections of the Gilenya data sheet in February 2019.

2.4.2 Gilenya UK Summary of Product Characteristics [24]**2.4.2.1 Special warnings and precautions for use****Tumefactive lesions**

Rare cases of tumefactive lesions associated with MS relapse were reported in the post-marketing setting. In case of severe relapses, MRI should be performed to exclude tumefactive lesions. Discontinuation of Gilenya should be considered by the physician on a case-by-case basis taking into account individual benefits and risks.

Return of disease activity (rebound)

In the post-marketing setting, severe exacerbation of disease has been observed rarely in some patients stopping fingolimod. The possibility of recurrence of exceptionally high disease activity should be considered (see "Stopping therapy" below).

Stopping therapy

If a decision is made to stop treatment with Gilenya a 6 week interval without therapy is needed, based on half-life, to clear fingolimod from the circulation. Lymphocyte counts progressively return to normal range within 1-2 months of stopping therapy in most patients although full recovery can take significantly longer in some patients. Starting other therapies during this interval will result in concomitant exposure to fingolimod. Use of immunosuppressants soon after the discontinuation of Gilenya may lead to an additive effect on the immune system and caution is therefore indicated.

Caution is also indicated when stopping fingolimod therapy due to the risk of a rebound (see “Return of disease activity (rebound)” above). If discontinuation of Gilenya is deemed necessary, patients should be monitored during this time for relevant signs of a possible rebound.

Comment

Tumefactive lesions were added to the Gilenya SmPC in the UK’s electronic Medicines Compendium in December 2018. See section 2.5 for more information.

2.5 International regulatory action

2.5.1 European Medicines Agency (EMA)

The EMA requested Novartis provide information about tumefactive lesions first in PSURs and then via a legally binding procedure (LEG 036), which resulted in an update to the summary of product characteristics (SmPC). [REDACTED]

[REDACTED] The following wording will be included, as requested by the EMA:

“Tumefactive lesions

Rare cases of tumefactive lesions associated with MS relapse were reported in the post-marketing setting. In case of severe relapses, MRI should be performed to exclude tumefactive lesions. Discontinuation of Gilenya should be considered by the physician on a case-by-case basis taking into account individual benefits and risks.”

Comment

The prescribing information in the European Union is being updated to include information about tumefactive lesions.

3.0 SCIENTIFIC INFORMATION

3.1 Published literature

3.1.1 Tls reported during treatment with fingolimod

3.1.1.1 Jander et al, 2012 [20]

This is a case report of a 49-year-old patient who developed a relapse with MRI features of tumefactive demyelination after switching therapy from natalizumab to fingolimod.

He was first diagnosed with MS in January 2010 and was initiated on natalizumab as first-line treatment with 4-weekly infusions. He remained stable but chose to discontinue natalizumab after 24 infusions as he was positive for anti-JC virus antibodies. In January 2012 he commenced fingolimod, 8 weeks after the last natalizumab infusion.

Eight weeks after initiation of fingolimod he presented with left-sided clinical symptoms and brain MRI showed multiple new Tls. Steroid pulse therapy led to rapid resolution of signs and symptoms. The option of switching therapy back to natalizumab was discussed with the patient who preferred to continue fingolimod. The patient remained stable with minimal residual deficit in the left-sided extremities. Brain MRI in March and July 2012 showed constant regression of the TL. The patient continued on fingolimod.

3.1.1.2 Hellman et al 2014 [25]

This is a case report of a 35-year-old female MS patient who developed a giant cavitating brain lesion under fingolimod (total treatment duration 22 months) and in whom cessation of therapy was associated with a very active disease course.

She was diagnosed at age 21 and started on glatiramer acetate therapy; for the next 10 years she had minor to moderate relapses, with an ARR of 0.5. At age 31 she had 3 moderate relapses requiring hospitalisation and her EDSS worsened from 2.5 to 4. She switched to interferon 1-beta but had 3 moderate relapses over the following 15 months, and EDSS worsened to 4.5.

She started fingolimod in August 2011. Two months later there was a relapse of severe optic neuritis and then a year of no relapses. In October 2012 there was a relapse of left hemiparesis that partially resolved following methylprednisolone treatment. In December 2012 an episode of severe left homonymous hemianopsia (visual field loss in same side of both eyes) evolved. Brain MRI showed typical non-enhancing MS lesions that had been seen before as well as a new occipital lesion that enhanced with gadolinium. She was treated with high-dose methylprednisolone then oral prednisone that was tapered over 2 months. A repeat MRI 4 months later showed decreased volume in the occipital lesion and no new lesions.

Six months after the initial left hemianopsia she started suffering from visual disturbances and other clinical symptoms. MRI revealed significant growth of the occipital lesion and new typical MS lesions. Fingolimod was suspended and high-dose steroids started, with some improvement in clinical symptoms. Steroids were stopped for 10 days to prepare for brain biopsy and an MRI taken at that time. The occipital lesion looked necrotic and no longer enhanced with gadolinium, but an extension of the lesion into the temporal lobe showed clear enhancement. Brain biopsy of this lesion showed a typical demyelinating lesion.

Two weeks later she suffered another relapse and was treated with high dose steroids then oral prednisone. There was some improvement and then another relapse. A new MRI revealed improvement of the occipital and temporal lesions but there were new, strongly enhancing lesions. High dose steroids and rituximab were started.

3.1.1.3 Harirchian et al, 2015 [22]

This is a case report of a 43-year-old Iranian man who was in good health until March 2009 when presented with right-sided paresthesia, diplopia, and vertigo. MRI revealed lesions suggestive of demyelinating disease. A second relapse occurred in August 2010 and RRMS was diagnosed and weekly interferon beta1-a treatment initiated. He relapsed in May 2013 and was switched to high-dose high-frequency interferon beta1-b. In August 2013 he switched to fingolimod due to adverse effects from interferon.

Other than first dose bradycardia, there were no reported adverse effects until 18 weeks after initiation of fingolimod, when the patient presented with headache, nausea, diplopia, blurred vision, and left hemisensory disturbance. TMs were diagnosed after MRI imaging and exclusion of other diagnoses. He was treated for 3 days with methylprednisolone pulse then prednisone for 20 days. The patient refused to start other second line MS therapies. After amelioration of clinical and radiological symptoms he was restarted on fingolimod. No new events were reported during one year of follow-up.

3.1.1.4 Okada et al, 2018 [26]

This case was a 50-year-old Japanese woman with a 10-year history of RRMS who was admitted to hospital because of difficulty conversing and performing activities of daily living.

She first presented with a brain stem lesion at age 31 years, following which she was diagnosed with RRMS on the appearance of a thoracic cord lesion at the age of 40 years. She was initiated on interferon-beta treatment following diagnosis but stopped due to depression. She experienced 2

relapses and was referred to the neurology unit at age 46 years. Fingolimod was introduced in Feb 2013 and she remained free of relapses. She was admitted to hospital in Aug 2016 (at age 50 years).

Neurologic examination revealed motor aphasia, ideational apraxia, and moderate right hemiparesis accompanied by mild weakness of the right facial muscles. Tendon reflexes were exaggerated in the right extremities. Typical oligoclonal bands (OCBs) were positive. Contrast-enhanced MRI revealed a massive lesion in the white matter of the left hemisphere. Biopsy and histopathologic analysis revealed inflammatory demyelination accompanied by parenchymal inflammatory infiltrates and perivascular lymphocytic cuffing (CD8-positive cytotoxic T lymphocytes and CD4-positive helper T cells, with relatively fewer B cells). Lymphoma and PML were excluded.

Two months after IV methylprednisolone and plasma exchange therapy, her symptoms gradually improved. Non-contrast-enhanced MRI revealed that the lesion had shrunk, and CSF analysis was normal. The patient again exhibited negative OCB findings.

3.1.2 TIs reported after cessation of fingolimod

3.1.2.1 Faissner et al 2015 [27]

This study presents the clinical and radiological findings of 2 patients who had a severe rebound after fingolimod withdrawal and compares these with 8 patients identified by a PubMed data bank analysis using the search term 'fingolimod rebound'. In total, 10 patients, of whom three developed TIs, are presented (Table 5).

Patient 1 was a 44-year-old female patient. MS was diagnosed in 2008 (aged 38 years at onset) and IM interferon beta-1a was initiated. This was withdrawn in 2012 due to cramps and worsening of gait ataxia. Two weeks later, in Nov 2012, fingolimod was initiated. During treatment, the patient was free of clinical and radiological signs of disease activity. She subsequently had 4 documented episodes of lymphopenia (range 70-370 per μL), and fingolimod was withdrawn in October 2013. She switched to dimethyl fumarate (DMF) in February 2014. In April 2014 she was admitted to hospital with paraesthesia and worsening of the paresis of the right leg (EDSS 5.0). WBC counts showed 6500 per μL leukocytes with 1180 per μL lymphocytes (18.9%). New lesions were revealed upon MRI. She was treated with IV methylprednisolone combined with two intrathecal triamcinolone injections and showed marked improvement of clinical symptoms (EDSS 4.5 in June 2014, 4.0 in Sept 2014) and MRI findings. DMF treatment was discontinued.

Patient 2 was a 36-year-old female patient with a disease course of 13 years. Relapses had occurred during therapy with interferon beta-1b, interferon beta-1a and glatiramer acetate. Natalizumab was started in September 2010. She had 24 natalizumab infusions and was free of RRMS disease activity during this time, but therapy was stopped due to severe bronchitis (classified as a possible adverse event) in Sep 2012. In March 2013 she started fingolimod. She was relapse free but therapy was stopped in December 2013 due to hospital admission for angina pectoris. DMF was started 7 weeks later, 1 week after that she developed cognitive decline, ataxia, disturbed balance and difficulties with writing and coordination. Cranial MRI in March 2014 showed multiple lesions and lymphocyte count was 1392 per μL (18.3%, 7610 leukocytes per μL). Treatment with IV methylprednisolone led to complete remission.

Including the cases extracted from the literature, the authors noted that the 3 patients with TIs were stable under fingolimod (Table 5) but numbers were too low for statistical analysis.

Table 5: Demographic and clinical data of all patients

PubMed ID	Sex	Age (years)	Age at onset	Age at MS diagnosis	Duration of FTY therapy (months)	EDSS end FTY	EDSS re-bound	EDSS end rebound	Number of previous MS therapies	FTY stable (1 = yes, 0 = no)	Reason for withdrawal	Considered as side effect? (1 = yes, 0 = no)	ARR FTY	Rebound after FTY withdrawal (weeks)	MS therapy during rebound? (1 = yes, 0 = no)	If MS therapy, weeks post FTY	If MS therapy, which treatment?	Tumefactive lesion (1 = yes, 0 = no)
22332194	m	45	35	35	48	2.5	4.5	3.5	1 (IFN-β1a)	1	malignant melanoma	1	0.8	12	0	none	none	0
23645219	f	19	11	11	5	3.5	na	3	1	0	lack of efficacy	0	na	7	0	none	none	0
23829238	f	31	24	24	14	0	3.5	na	2	1	wish to become pregnant	0	0	11	0	none	none	0
22829326	f	33.5	30.9	na	30	2	4	3	na	1	suspected infection of CNS (was excluded)	0	0.4	12	0	none	none	0
23035074	m	29	22	22	42	na	na	na	0	1	Herpes zoster infection	1	na	28	1	20	IFN-b 1a 44 µg	1
24756193	f	36	19	19	4	6	6.5	6	1	1	lymphopenia	1	0	16	0	none	none	0
23161460	f	47	30	35	89	7	7	7	2 (IFN-β, glatiramer acetate)	0	lack of efficacy	0	na	16	0	none	none	0
23161460	f	30	20	20	15	1.5	4	2.5	2 (glatiramer acetate, IFN-β)	0	genital human papilloma virus infection	1	na	8	0	none	none	0
Patient 1	f	44	38	38	13	4	5	4.5	1 (IFN-β1a)	1	lymphopenia	1	0	8	1	8	DMF	1
Patient 2	f	36	23	23	9.5	3	4	4	4 (IFN-β1b s.c. 250 µg, IFN-β1a s.c. 3 × 22 µg and 44 µg, glatiramer acetate, natalizumab)	1	angina pectoris	1	0	8	1	7	DMF	1

3.1.2.2 Salam et al, 2016 [28]

A 32-year-old woman with RRMS escalated treatment from interferon beta to fingolimod due to ongoing relapses. She developed side effects on fingolimod including persistent lymphopenia (<0.3). The fingolimod dose was reduced to alternate days. The patient noticed cognitive decline with progressive memory loss. MRI with contrast showed ongoing MS disease activity, but no evidence of progressive multifocal leukoencephalopathy. The patient discontinued fingolimod in May 2015. However, only by July 2015 did the side effects related to fingolimod resolve. The patient started a modified diet and low-dose naltrexone therapy. She declined treatment with alemtuzumab but did consent to MRI. In August 2015 she was admitted with severe MS relapse. MRI demonstrated severe rebound disease and numerous contrast-enhancing tumefactive MS lesions. She was treated with intravenous steroids and alemtuzumab leading to partial neurological recovery after 6 months.

3.1.2.3 Sato et al, 2018 [15]

The Japanese study determined the follow-up status of MS patients who switched to DMF after fingolimod cessation. Clinical and MRI data in 19 patients with MS who switched to DMF were collected for at least for 6 months after fingolimod cessation; 3 of whom experienced disease exacerbation and developed TLs.

Ten patients (52.6%), all of whom had switched from interferon 1-beta to fingolimod, experienced clinical or MRI exacerbation after fingolimod cessation (Table 6). These 10 patients were further classified into three groups based on MRI findings. The characteristics of the 9 patients who did not experience disease exacerbation are summarised in Table 7.

- Group I (patients 1-3) –those with ≤ 3 new lesions on MRI. However, the clinical and MRI findings at the time of relapse were not markedly different from those during or prior to fingolimod treatment, suggesting that their disease activity did not change during or prior to fingolimod treatment.
- Group II (patients 4-7) – those with ≥ 4 enhanced lesions (>10 lesions in most cases) but no TLs after fingolimod cessation. These multiple enhanced lesions had never been observed prior to fingolimod induction in those patients.
- Group III (patients 8-10) –those with multifocal TLs that were not evident before fingolimod initiation.
 - In patient 8, disease activity persisted despite fingolimod treatment (120 weeks). MRI 35 days after fingolimod cessation revealed multifocal TLs without any clinical signs. DMF and high-dose corticosteroids were initiated and MRI showed marked improvement. No further TLs appeared but new enhanced lesions were observed on MRI at 99, 127 and 168 days after fingolimod cessation despite DMF treatment.
 - In patient 9, disease activity was stable during fingolimod treatment (84 weeks), and brain MRI was stable at 28 days after cessation. DMF was started 36 days after cessation. Patient had fatigue and dizziness 80 days after fingolimod cessation and MRI at 91 days after cessation revealed multifocal TLs. High-dose corticosteroids were given and the TLs and clinical condition of the patient improved. Additional new enhanced lesions were observed at 119 and 173 days after cessation, despite DMF treatment.
 - In patient 10, disease activity was stable during fingolimod treatment (144 weeks). However, the patient experienced weakness and numbness in the left lower limb with new T2-weighted lesions on brain MRI 21 days after fingolimod cessation. The clinical deterioration responded to high-dose steroids; however the patient experienced new symptoms 42 days after fingolimod cessation and high-dose steroids were restarted and DMF initiated. MRI at 63 days after fingolimod cessation revealed further expansion of multiple TLs. Steroid pulse therapy was initiated, and there was slight improvement in the TLs at 78 days after cessation. Subsequently, the clinical signs recovered completely and the TLs improved gradually.

However, additional new enhanced lesions were observed at 89 and 149 days after fingolimod cessation despite DMF treatment.

Table 6: Demographic and clinical characteristics of 10 patients with MS who experienced clinical or MRI exacerbation after fingolimod cessation

Patient No.	Group I				Group II			Group III		
	1	2	3	4	5	6	7	8	9	10
Sex	F	F	F	F	M	F	F	F	F	F
At fingolimod initiation										
<i>Disease duration (years)</i>	1	4	2	13	37	13	23	3	7	5
<i>ARR (preceding year)</i>	3	2	1	0	1	1	1	0	1	1
<i>Clinical course</i>	RR	RR	RR	SP	RR	SP	SP	mono	RR	RR
<i>EDSS</i>	6.5	1.0	2.5	6.5	2.5	4.5	4.5	0.0	1.5	0.0
During fingolimod therapy										
<i>Duration of fingolimod treatment (weeks)</i>	124	264	144	260	248	202	152	120	84	144
<i>ARR</i>	3	0	0	0	0	0	0	0	0	0.36
<i>EDSS</i>	6.5	1.0	2.5	6.5	2.5	4.5	4.5	0.0	1.5	0.0
Age at fingolimod cessation (years)	54	37	36	46	59	44	58	34	45	39
Clinical or MRI exacerbation after fingolimod cessation										
<i>Time from fingolimod cessation (days)</i>	16	98	87	52	42	140	141	36	91	21
<i>EDSS</i>	7.0	1.5	3.5	7.5	2.5	4.5	4.5	0.0	1.5	2.5
Days from fingolimod cessation to DMF initiation	41	n.i.	134	64	43	32	84	35	36	43
Peripheral blood lymphocyte count (μ L)										
<i>At fingolimod cessation</i>	530	372	103	90	497	481	326	411	479	368
<i>4 weeks after fingolimod cessation</i>	1,431	499	297	1,468	1,081	979	638	1,209	1,191	718

ARR: annual relapse rate, EDSS: expanded disability status scale, DMF: dimethyl fumarate, MRI: magnetic resonance imaging, RR: relapsing-remitting, SP: secondary progressive, mono: monophasic, n.i.: not induced

Table 7: Demographic and clinical characteristics of 9 patients with MS who did not experience clinical nor MRI exacerbation after fingolimod cessation

Patient No.	11	12	13	14	15	16	17	18	19
Sex	F	F	M	F	F	M	M	F	M
At fingolimod initiation									
<i>Disease duration (years)</i>	3	5	6	32	13	15	11	0.5	7
<i>ARR (preceding year)</i>	0	1	0	2	0	0	0	1	0
<i>Clinical course</i>	RR	RR	SP	SP	SP	RR	SP	RR	RR
<i>EDSS</i>	1.0	1.5	5.5	7.0	4.5	0.0	6.5	0.0	0.0
During fingolimod therapy									
<i>Duration of fingolimod treatment (weeks)</i>	216	56	48	126	182	270	112	243	113
<i>ARR</i>	0.24	0	0	0.41	0	0	0	0	0
<i>EDSS</i>	1.0	1.5	5.5	7.0	4.5	0.0	7.0	0.0	0.0
Age at fingolimod cessation (years)	45	33	48	53	49	44	41	23	43
Days from fingolimod cessation to DMF initiation	77	42	35	41	43	72	34	34	30
Peripheral blood lymphocyte count (μ L)									
<i>At fingolimod cessation</i>	667	701	777	711	720	673	2,628	819	621
<i>4 weeks after fingolimod cessation</i>	939	1,072	1,350	1,339	1,081	807	3,083	1,347	1,198

ARR: annual relapse rate, EDSS: expanded disability status scale, DMF: dimethyl fumarate, MRI: magnetic resonance imaging, RR: relapsing-remitting, SP: secondary progressive, mono: monophasic

There were no significant differences between the exacerbation and non-exacerbation groups for the age at fingolimod cessation, sex, clinical course, disease duration, EDSS, or ARR at fingolimod initiation or during fingolimod treatment.

The peripheral total lymphocyte counts (TLCs) at 4 weeks after fingolimod cessation were significantly higher than those at the time of fingolimod cessation (baseline) in both the exacerbation and non-exacerbation groups. At the time of fingolimod cessation, the peripheral TLCs of the exacerbation group were significantly lower than those in the non-exacerbation group ($p < 0.001$), but 4 weeks after fingolimod cessation the difference were no longer significant. The ratio of TLCs at 4 weeks after fingolimod cessation to those at the time of fingolimod cessation was significantly higher in the exacerbation group than in the non-exacerbation group ($p < 0.01$).

3.1.3 Tls reported during treatment or after cessation

3.1.3.1 Sánchez et al, 2017 [18]

This was a retrospective review of 15 TL cases (12 women and 3 men) treated at a demyelinating disorders unit in a Spanish hospital from January 2010 to February 2017.

The mean age of TL onset was 36 years. Out of the 15 patients, 9 had Tls as a first demyelinating event and 44% (4/15) of these converted to MS in a mean time of 8 months (SD 3.10). Five patients had been previously diagnosed with RRMS and 1 with clinically isolated syndrome.

Clinical presentation was polysymptomatic and the most common radiological findings were single Tls (67%), located primarily in the frontal (40%) or parietal (33%) lobes. MS was the most common diagnosis (67%, 10/15). Acute treatment included steroids, plasmapheresis, rituximab and cyclophosphamide.

The 5 patients with a previous MS diagnosis had all received fingolimod as disease modifying therapy. Of these, 4 of the TL cases occurred after cessation of therapy, while another patient

developed TLs during treatment with fingolimod. These 5 cases are described in Sanchez et al, 2018 [23].

3.1.3.2 Sánchez et al, 2018 [23]

This study was a retrospective review of medical records of MS patients from a demyelinating disorders unit in a Spanish hospital, who were treated with fingolimod and developed TLs. The authors found 5 cases: 4 developed TLs as rebounds after fingolimod treatment cessation and 1 under treatment. TLs were multiple in 2 cases and solitary in 3. Acute treatment for rebound included high dose steroids (5/5), plasma exchange (3/5) and rituximab (2/5). Treatment after fingolimod included rituximab (2/5), alemtuzumab (2/5) and glatiramer acetate (1/5).

The 4 rebound cases were women, with a mean age of 34.7 years (SD=3.6) and a mean disease duration of 10.2 years (SD=4.1) (Table 8). The mean duration of fingolimod treatment before discontinuation was 36.2 months (SD=22.4) and the mean time lapse between treatment withdrawal and rebound was 9.75 weeks (SD=7.4). The total pre-rebound lymphocyte count (cells/mm³) was 482.5 (SD=325.7) and 1017.5 (SD=364.8) during rebound.

Table 8: Comparative table of patients with TLs after fingolimod discontinuation


Patient	Age, sex	Disease duration (years)	Previous DMT	EDSS pre-rebound	EDSS during rebound	Duration of FTY treatment (months)	Time to rebound after FTY withdrawal (weeks)	Lymphocyte count before FTY Withdrawal (cel/mm ³)	Lymphocyte count during rebound (cel/mm ³)	Acute treatment	DMT post-rebound	Reason for discontinuation
1	34, F	15	Interferon beta-1a	2	3	35	14	550	1090	Steroids	Glatiramer acetate	Pregnancy planning
2	40, F	5	Glatiramer acetate natalizumab	2	8	6	18	910	1500	Steroids, PLEX, rituximab	Rituximab	Intolerance
3	32, F	11	Interferon beta-1b, glatiramer acetate	6.5	8	59	4	300	800	Steroids, PLEX	Alemtuzumab	Treatment failure and adverse effects
4	33, F	10	Interferon beta-	1.5	6	45	3	170	680	Steroids, PLEX, rituximab	Rituximab	Persistent severe lymphopenia


*DMT = Disease modifying therapy; FTY = Fingolimod; F = female, PLEX = Plasma exchange


The TL patient under fingolimod was a 36-year-old man who had been stable on fingolimod for 32 months after switching from glatiramer acetate. He developed a brainstem attack and new activity on MRI so a switch to alemtuzumab was decided. Before fingolimod was stopped he presented with 2 epileptic seizures. MRI showed a large left frontal TL. Other diagnoses were ruled out, and he was treated with IV steroids. Alemtuzumab was started with good clinical response.


Comment


These studies, primarily describing case reports or case series, are heterogeneous in nature. There are no identifiable patient characteristics that might increase the risk of TLs; and TTO of the TLs, pre-existing treatment, clinical symptoms associated with TLs and their outcome varies between study patients.

















3.3 Individual case reports


3.3.1 New Zealand


As at 29 January 2019, there were 24 reports in the CARM database for fingolimod, none of which were for tumefactive lesions. There have been no neurological reactions reported for fingolimod.














4.0 DISCUSSION AND CONCLUSIONS

Multiple sclerosis (MS) is a progressive, potentially disabling autoimmune disease of the central nervous system that damages myelin, the protective layer surrounding nerves. This disrupts communication to and from the brain and produces a variety of clinical symptoms. MS affects 2.5 million people worldwide, and approximately 85% have a relapsing form of the disease at onset. Women are 2-3 times more likely to have MS than men. Disease-modifying therapies aim to reduce the frequency of relapses as well as reducing the severity of relapses to reduce the build-up of disability. Fingolimod is a funded, first-line treatment for MS in New Zealand.

Fingolimod modulates the S1P1 receptor in the lymph nodes which causes a redistribution of lymphocytes. This redistribution reduces the infiltration of pathogenic lymphocyte cells into the central nervous system where they would be involved in nerve inflammation and nervous tissue damage. Fingolimod is a non-selective S1P receptor antagonist and also modulates S1P receptors in other tissues – some of which have immunologic effects.

Rebound and severe disease exacerbation following discontinuation of fingolimod has been reported. Various mechanisms for this have been proposed but none have been confirmed. The Gilenya data sheet has recently been updated to include warnings about return of disease activity (rebound) after Gilenya discontinuation.

TLs are large (>2 cm), tumour-like demyelinating lesions in the CNS that may occur with surrounding oedema, mass effect, and ring enhancement. Tumefactive lesions are difficult to diagnose and there are varying estimates for prevalence and incidence. TLs have been identified in patients before and after MS is diagnosed, and during and after DMT treatment, including in association with fingolimod.

The pathogenesis of TL remains unknown. Antibody-mediated and B cell-mediated immunological mechanisms may play a role as well as inflammatory cytokines such as tumour necrosis factor- α and interleukin-1 β , which are toxic to both myelin and oligodendrocytes.

Fingolimod has been reported in association with TL, both upon initiation of therapy and after its cessation. Hypotheses on the underlying mechanism of fingolimod-induced TLs are diverse and include: unusual activation of immune system, redistribution of immune cells, lymphocyte subset shift, transient inhibition of regulatory cells, and the role of altered S1P1 receptor genotype.

The TL cases reported in the literature are heterogeneous. There are no identifiable patient characteristics that might predispose the patient to developing TLs. The time to onset of the TLs, pre-existing treatment, clinical symptoms associated with TLs and outcome varies between the study patients.

Tumefactive lesions are not listed in the NZ Gilenya data sheet but have been added to the warnings and precautions section of the EU prescribing information, following PRAC review:

“Tumefactive lesions

Rare cases of tumefactive lesions associated with MS relapse were reported in the post-marketing setting. In case of severe relapses, MRI should be performed to exclude tumefactive lesions. Discontinuation of Gilenya should be considered by the physician on a case-by-case basis taking into account individual benefits and risks.”

There have been no NZ reports of TLs in association with fingolimod.

5.0 ADVICE SOUGHT

The committee is asked to advise if there is sufficient evidence for an association between fingolimod and tumefactive lesions, and if so:

- is a data sheet update required
- does this topic require further communication, other than MARC’s remarks in *Prescriber Update*?

█ █
 █ █
 █ █
 █ █

7.0 REFERENCES

1. Gilmour H, Ramage-Morin P and Wong S. 2018. Multiple sclerosis: prevalence and impact. *Statistics Canada - Health Reports* 29(1): 3-9. URL; <https://www150.statcan.gc.ca/n1/pub/82-003-x/2018001/article/54902-eng.htm>(accessed 15 February 2019).
2. Pelletier D and Hafler D. 2012. Fingolimod for multiple sclerosis. *New England Journal of Medicine* 366(January 26): 339-47. DOI: 10.1056/NEJMct1101691 (accessed 8 February 2019).
3. Broadley S, Barnett M, Boggild M, et al. 2014. Therapeutic approaches to disease modifying therapy for multiple sclerosis in adults: an Australian and New Zealand perspective – Part 1 Historical and established therapies. *Journal of Clinical Neuroscience* 21(11): 1835-46. DOI: 10.1016/j.jocn.2014.01.016 (accessed 12 February 2019).

4. Olek M and Howard J. 2018. Clinical presentation, course, and prognosis of multiple sclerosis in adults. In: *UpToDate* 28 September 2018. URL: <https://www.uptodate.com/contents/clinical-presentation-course-and-prognosis-of-multiple-sclerosis-in-adults> (accessed 9 January 2019).
5. Alla S, Pearson J, Taylor B, et al. 2016. Disability profile of multiple sclerosis in New Zealand. *Journal of Clinical Neuroscience* 28(June): 97-101. DOI: 10.1016/j.jocn.2015.09.020 (accessed 8 February 2019).
6. Alla S and Mason D. 2014. Multiple sclerosis in New Zealand. *Journal of Clinical Neuroscience* 21(8): 1288-91. DOI: 10.1016/j.jocn.2013.09.009 (accessed 8 February 2019).
7. Alla S, Pearson J, Richardson A, et al. 2015. *The incidence of multiple sclerosis in New Zealand: A prospective, nationwide population-based study*. URL: <https://msresearch.nz/wp-content/uploads/2015/05/NZ-Incidence-Study.pdf> (accessed 12 February 2019).
8. Multiple Sclerosis New Zealand. 2017. *MS Treatments* URL: <https://www.msnz.org.nz/ms-treatments/> (accessed 21 February 2019).
9. Broadley S, Barnett M, Boggild M, et al. 2014. Therapeutic approaches to disease modifying therapy for multiple sclerosis in adults: an Australian and New Zealand perspective – Part 2 New and emerging therapies and their efficacy. *Journal of Clinical Neuroscience* 21(11): 1847-56. DOI: 10.1016/j.jocn.2014.01.018 (accessed 12 February 2019).
10. Novartis New Zealand Limited. 2018. *Gilenya 0.5 mg capsules New Zealand Data Sheet* 13 July 2018. <https://www.medsafe.govt.nz/profs/Datasheet/g/gilenyacap.pdf> (accessed 8 February 2019).
11. Chaudry B, Cohen J and Conway D. 2017. Sphingosine 1-phosphate receptor modulators for the treatment of multiple sclerosis. *Neurotherapeutics* 14(4): 859-73. DOI: 10.1007/s13311-017-0565-4 (accessed 12 February 2019).
12. Ingwersen J, Aktas O, Juery P, et al. 2012. Fingolimod in multiple sclerosis: mechanisms of action and clinical efficacy. *Clinical Immunology* 142(1): 15-24. DOI: 10.1016/j.clim.2011.05.005 (accessed 12 February 2019).
13. Yoshii F, Moriya Y, Ohnuki T, et al. 2017. Neurological safety of fingolimod: an updated review. *Clinical & Experimental Neuroimmunology* 8(3): 233-43. URL: <https://www.ncbi.nlm.nih.gov/pmc/articles/PMC5575715/> (accessed 8 February 2019).
14. Algahtani H, Shirah B and Alassiri A. 2017. Tumefactive demyelinating lesions: a comprehensive review. *Multiple Sclerosis and Related Disorders* 14(May): 72-9. DOI: 10.1016/j.msard.2017.04.003 (accessed 12 February 2019).
15. Sato K, Niino M, Kawashima A, et al. 2018. Disease exacerbation after the cessation of fingolimod treatment in Japanese patients with multiple sclerosis. *Internal Medicine* 57(18): 2647-55. URL: <https://www.ncbi.nlm.nih.gov/pmc/articles/PMC6191590/> (accessed 8 February 2019).
16. Pharmaceutical Management Agency. 2015. *Year in Review 2015*. URL: <https://www.pharmac.govt.nz/assets/year-in-review-2015.pdf> (accessed 12 February 2019).
17. Mando R, Muallem E, Meka S, et al. 2018. A blind spot in the diagnostic field: the challenging diagnosis of tumefactive multiple sclerosis. *Case Reports in Neurological Medicine* 27(June): 6841291. DOI: 10.1155/2018/6841291 (accessed 7 February 2019).
18. Sánchez P, Meca-Lallana V, Barbosa A, et al. 2017. Tumefactive demyelinating lesions of 15 patients: Clinico-radiological features, management and review of the literature. *Journal of*

- the Neurological Sciences* 381(15 October): 32-8. URL: <https://doi.org/10.1016/j.jns.2017.08.005> (accessed 11 February 2019).
19. Lucchinetti C, Gavrilova R, Metz I, et al. 2008. Clinical and radiographic spectrum of pathologically confirmed tumefactive multiple sclerosis. *Brain* 131(7): 1759-75. URL: <https://www.ncbi.nlm.nih.gov/pmc/articles/PMC2442427/pdf/awn098.pdf>(accessed 20 February 2019).
 20. Jander S, Turowski B, Kieseier B, et al. 2012. Emerging tumefactive multiple sclerosis after switching therapy from natalizumab to fingolimod. *Multiple Sclerosis* 18(1650-2). DOI: <https://doi.org/10.1177/1352458512463768> (accessed 12 February 2012).
 21. Pilz G, Harrer A, Wipfler P, et al. 2013. Tumefactive MS lesions under fingolimod: a case report and literature review. *Neurology* 81(19): 1654-8. DOI: 10.1212/01.wnl.0000435293.34351 (accessed 11 February 2019).
 22. Harirchian M, Taalimi A and Siroos B. 2015. Emerging tumefactive MS after switching therapy from interferon-beta to fingolimod: a case report. *Multiple Sclerosis & Related Disorders* 4(5): 400-02. DOI: 10.1016/j.msard.2015.05.007 (accessed 20 February 2019).
 23. Sánchez P, Meca-Lallana V and Vivancos J. 2018. Tumefactive multiple sclerosis lesions associated with fingolimod treatment: Report of 5 cases. *Multiple Sclerosis & Related Disorders* 25(October): 95-8. DOI: 10.1016/j.msard.2018.07.001 (accessed 7 February 2019).
 24. electronic Medicines Compendium (eMC). 2019. *Gilenya 0.5 mg hard capsules - SmPC* 17 December 2018. URL: <https://www.medicines.org.uk/emc/product/4545> (accessed 19 February 2019).
 25. Hellmann M, Lev N, Lotan I, et al. 2014. Tumefactive demyelination and a malignant course in an MS patient during and following fingolimod therapy. *Journal of Neurological Sciences* 344(1-2): DOI: 10.1016/j.jns.2014.06.013 (accessed 20 February 2019).
 26. Okada K, Hashimoto T, Kobata M, et al. 2018. Tumefactive demyelination with a transient appearance of oligoclonal bands in MS under fingolimod. *Neurol Neuroimmunol Neuroinflamm* 5(e484). URL: <https://www.ncbi.nlm.nih.gov/pmc/articles/PMC6039211/pdf/NEURIMMINFL2018016758.pdf> (accessed 8 February 2019).
 27. Faissner S, Hoepner R, Lukas C, et al. 2015. Tumefactive multiple sclerosis lesions in two patients after cessation of fingolimod treatment. *Therapeutic Advances in Neurological Disorders* 8(5): 233-8. URL: <https://www.ncbi.nlm.nih.gov/pmc/articles/pmid/26557898/> (accessed 8 February 2019).
 28. Salam S, Mihalova T and Siripurapu R. 2016. Severe tumefactive rebound of multiple sclerosis following fingolimod cessation. *BMJ Case Reports* 2016(June 3): bcr2016215596. URL: <https://www.ncbi.nlm.nih.gov/pmc/articles/PMC4904436/> (accessed 8 February 2019).
 29. Totaro R, Di Carmine C, Splendiani A, et al. 2016. Occurrence and long-term outcome of tumefactive demyelinating lesions in multiple sclerosis. *Neurological Sciences* 37(7): 1113-17. DOI: 10.1007/s10072-016-2558-1 (accessed 20 February 2019).
 30. Altintas A, Petek B, Isik N, et al. 2012. Clinical and radiological characteristics of tumefactive demyelinating lesions: follow-up study. *Multiple Sclerosis* 18(10): 1448-53. DOI: 10.1177/1352458512438237 (accessed 20 February 2019).
 31. Kantorová E, Bittšanský M, Sivák Š, et al. 2017. Anaplastic astrocytoma mimicking progressive multifocal leucoencephalopathy: a case report and review of the overlapping syndromes. *BMC Cancer* 17(1): 424. URL: <https://www.ncbi.nlm.nih.gov/pmc/articles/pmid/28629398/> (accessed 8 February 2019).